

Back to your roots!

MI treatment solutions for root caries

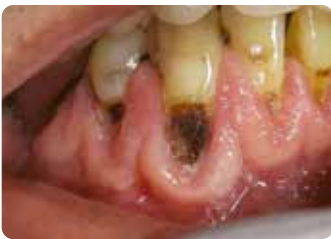

Since 1921
100 years of Quality in Dental



Root caries and the ageing population

Challenges in dentate older adults



Courtesy Wim Klüter, The Netherlands

Steady increases in both the absolute and relative numbers of older people – together with increased tooth retention into old age¹ – pose particular challenges for the dental practice. Aside from the repair and replacement of failed restorations, root caries will become a daily challenge within the ageing population. Once exposed to the oral environment, root surfaces are at greater risk of demineralisation, especially when patients have reduced saliva flow and diminished buffering capabilities.^{2,3} It is essential to approach root caries in a holistic way: identify the risk factors, prevent them from occurring and restore the already present cavities in a minimally invasive way.

Risk factors related to ageing

- Reduced salivary flow and/or salivary pH: less buffering capacity to counteract acid attacks
- General and oral health pathologies: risk of (co)morbidities
- Medication intake and polypharmacy: risk of side effects, e.g. xerostomia
- Reduction in fine motor skills: difficulties in maintaining oral hygiene
- Reduced abilities to cooperate because of cognitive or functional aspects: e.g. dementia, severe tremor, ...
- High dependency level: difficulties in finding dental care, e.g. not able to come to the dental office
- Diet changes to increased sugar intake; increased preference for sweets

Identify

GC Tri Plaque ID Gel: identify new, old, and acid-producing plaque

Using identification tools such as **GC Tri Plaque ID Gel** can help to identify cariogenic plaque, motivate patients and give them or their caretakers straightforward and objective feedback to optimise their brushing technique.

Pink/red
Immature biofilm < 48h

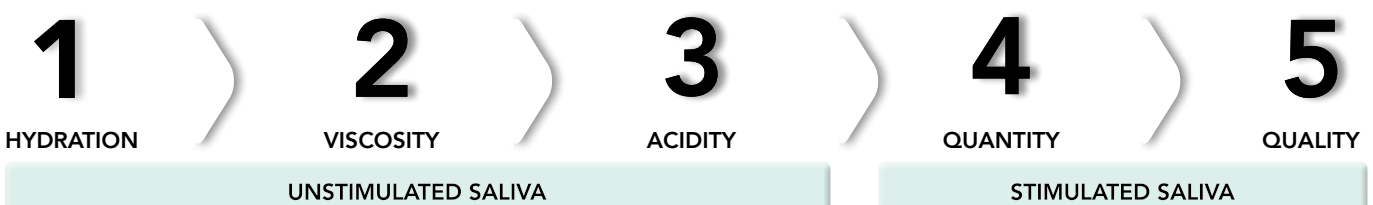Blue/purple
Complex biofilm > 48h
Risk of gingivitis

Light blue
Acidic plaque with pH < 4.5
This is a high-risk biofilm.

GC Tri Plaque ID Gel discloses the age and acidity of the biofilm
Courtesy Dr Andrew Brostek, Australia

Saliva-Check BUFFER: how well does the saliva protect the teeth?

Chronic dry mouth and reduced salivary function due to various aetiologies occur in a substantial proportion of older people. In 5 easy steps, **Saliva-Check BUFFER** helps to reveal underlying factors that disrupt the oral balance and cause demineralisation.³



Protect and prevent

GC MI Paste Plus and MI Varnish: strengthen and desensitise

The presence of fluoride and amorphous calcium phosphate in the saliva creates a favourable environment for tissue remineralisation.

Topical fluoride must be used at home and must be supplemented with regular professional application of fluoride varnish. Adjunctive use of bio-available calcium phosphates favours tooth repair and has shown impressive results in reducing hypersensitivity.^{4,5}

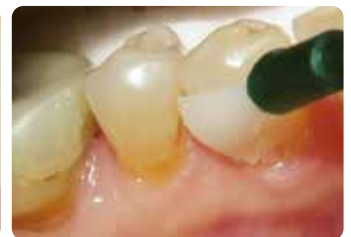
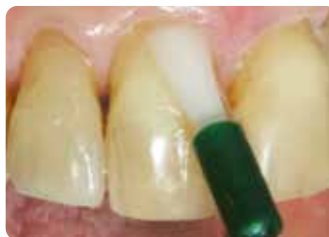
GC MI Paste Plus contains RECALDENT (bio-available amorphous calcium phosphate; CPP-ACP) as well as fluoride (900 ppm). It can be used overnight to enhance tooth repair and reduce hypersensitivity. It is available in 5 delicious flavours that increase patient acceptance. Patients with decreased salivary flow tend to show a preference for Vanilla flavour.



GC MI Paste Plus in 5 delicious flavours (left) and its fluoride-free alternative GC Tooth Mousse (right).

MI Varnish contains 22600 ppm fluoride as well as RECALDENT (CPP-ACP) and is intended for in office application. It adheres quickly to the teeth, without clumping and serves as a depot for minerals and fluoride, necessary to maintain or remedy the tooth integrity. RECALDENT (CPP-ACP) and fluoride work in synergy: when RECALDENT (CPP-ACP) comes in contact with fluoride, it stabilises the fluoride ions to create the ideal source for building the more acid-resistant fluorapatite.



In office application of MI Varnish
Courtesy Prof. Ian Meyers, Australia

RECALDENT™ is derived from milk casein. Do not use on persons with a milk allergy. In case of allergic reaction: stop use, rinse mouth with water, and seek medical advice.

GC Dry Mouth Gel: alleviate xerostomia

Dry Mouth Gel is a unique, sugar-free product to give long lasting comfort and to sooth symptoms of oral dryness. Uniquely, unlike most saliva substitutes, it has a neutral pH, preserving the oral pH within the safe range to prevent demineralization. It is colourless and comes in various pleasant flavours.

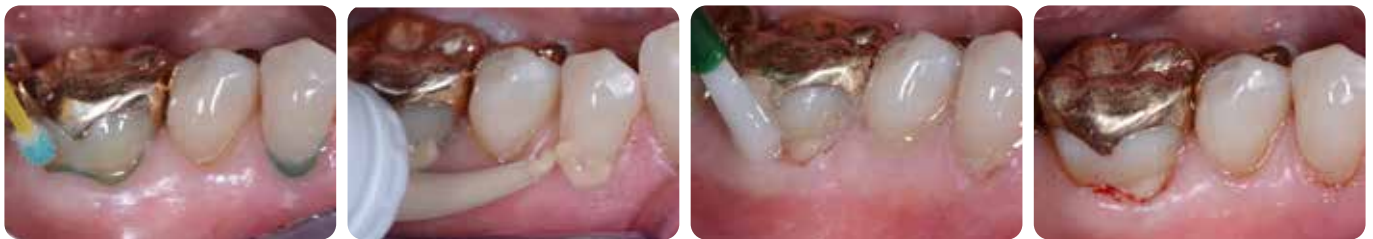Use Dry Mouth Gel for relief during the day; for night-time prevention, MI Paste Plus is recommended to provide additional protection against caries, promote remineralisation and prevent and relieve hypersensitivity from exposed roots. Dry Mouth gel does not interfere with the effectiveness of RECALDENT (CPP-ACP) or fluoride, so they can safely complement each other.



Managing erosion, oral hygiene challenges and exposed roots with **Fuji TRIAGE**

Fuji TRIAGE, a fluid glass ionomer, will help to protect the surface against caries formation and hypersensitivity

- Fuji TRIAGE can bond chemically in a relatively moist environment⁶
- Root surfaces are fast and easily protected
- The setting of the pink shade of Fuji TRIAGE can be accelerated with the dental curing light
- Fuji TRIAGE can be coated with MI Varnish to boost the ion exchange



Restoration of root caries lesions with Fuji TRIAGE, followed by MI Varnish application.
Courtesy Prof Matteo Basso, Italy

Treat and control

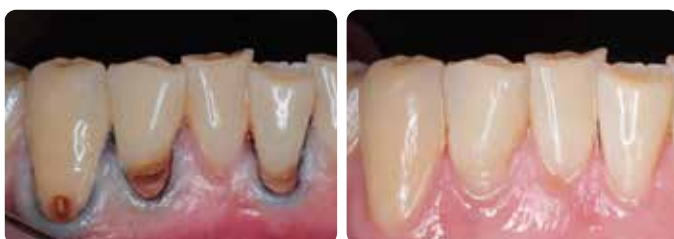Minimally invasive restoration of root caries

A restoration does not remove the cause of the lesion; hence, to avoid lesion progression, it should always be combined with preventive strategies

- Sites of plaque retention are removed by restoring a smooth surface
- The caries-affected dentine in the central part of the lesion does not need to be entirely removed; hence, the risk of pulp exposure/pulp infection is reduced, and the remaining tooth structure is weakened less
- Glass ionomers, glass hybrids or composites can be used to restore root caries lesions. The best choice depends on the oral circumstances, preferences of the patient and practitioner as well as the ability of the patient to cooperate.

Control over speed with **Fuji II LC**

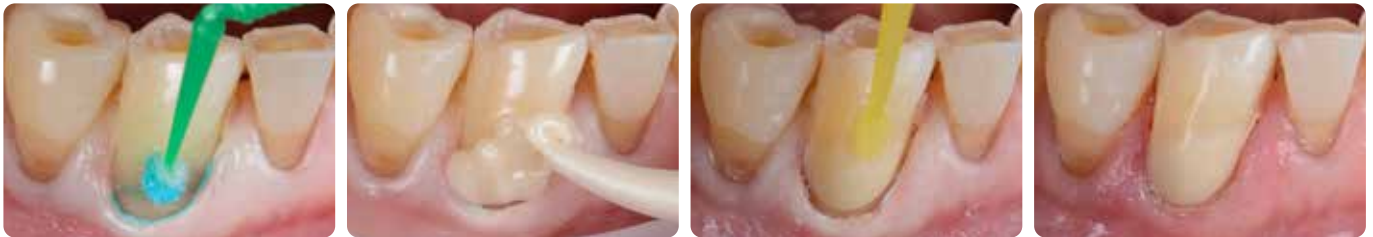Fuji II LC is indicated for any case where speed and ease of use are priorities. This might be the case in patients who cannot cooperate well, lacking the necessary cognitive or physical abilities to fully cooperate. These restorations show good survival rates.⁷



MI restorations of root caries lesions with Fuji II LC, one month after placement.
Courtesy Dr AmrEldeeb Core Team, Ain Shams University, Cairo, Egypt

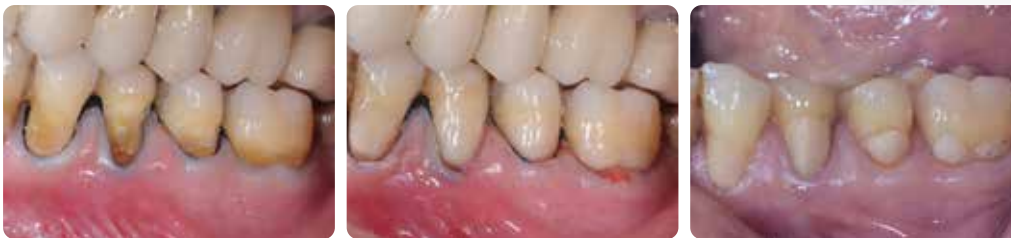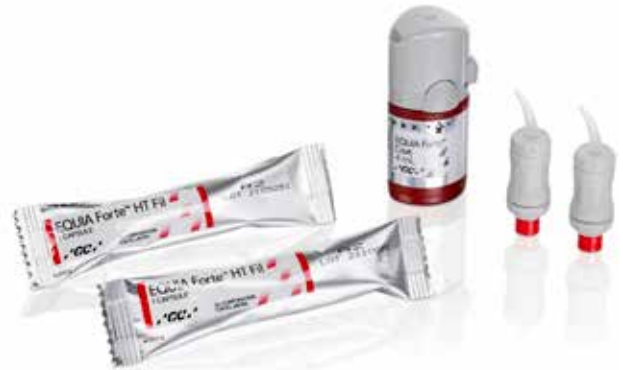Durable restorations placed fast and providing caries protection: EQUIA Forte HT

EQUIA Forte HT, a glass hybrid restorative, has a pleasant consistency to pack and contour. The EQUIA Forte Coat gives it a nice, wear resistant finish and gloss, and additionally adds to its strength by creating the right environment for the material to mature and strengthen. Its ease of placement is especially convenient when treating root caries because of the moisture tolerance and the speed of treatment; it can even be sculpted simply by using a finger. Moreover, through ion exchange, these restorations stimulate tooth remineralisation and prevent demineralisation and therefore the best option for active lesions.



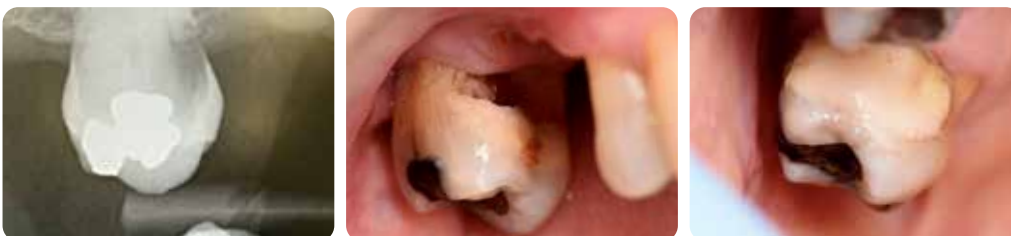Cervical restoration with EQUIA Forte HT
Courtesy Dr Javier Tapia Guadix, Spain

The advantages of glass hybrids for restoring cervical lesions have been demonstrated in randomized controlled trials of a robust design.⁸ Even though this is not surprising, it should be highlighted that the cost-effectiveness in comparison with composites turned out beneficial, initially as well as in the long term.⁹



EQUIA Forte (the predecessor of EQUIA Forte HT) restorations before treatment (left), at baseline (middle) and after 6.5 years of function (right).
Courtesy Prof. Matteo Basso, Italy

Even though in many cases, Atraumatic Restorative Treatment (ART) won't be the first option, this technique can be applied in case of highly dependent patients who do not manage to come to the dental practice or in any other situation where the use of rotary instruments is not an option.^{6,10} Powder/Liquid versions are available to work in absence of a capsule mixer. In the ART technique, only the infected dentine is removed but the affected/ leathery dentine close to the pulp is kept, which helps keeping pulp vitality and avoids sensitivity. Perfectly clean margins will ensure the success of the restoration. In most cases, anaesthesia is not necessary.

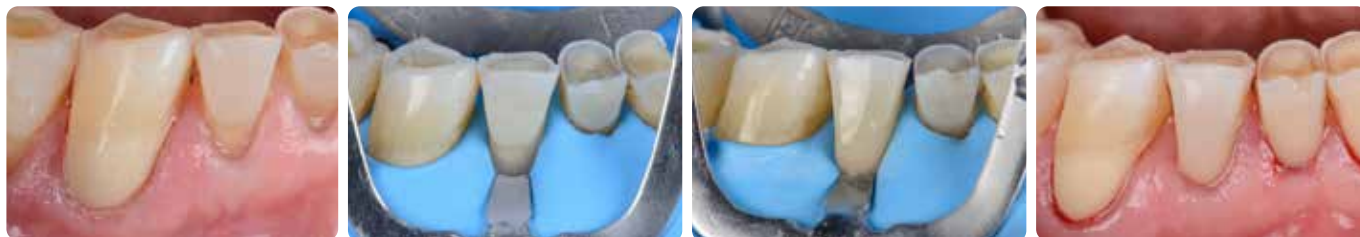

ART subgingival restoration with EQUIA Forte HT
Courtesy Prof. Gerry McKenna, United Kingdom

Aesthetic restorations with G-ænial Universal Injectable

When the lesion is non-carious or arrested and there is a possibility to isolate well with rubber dam, **G-ænial Universal Injectable** is an excellent restorative option for root caries lesions. It can easily be polished to high gloss, which reduces plaque retention, and it is wear resistant, which is important in these areas that are subjected to abrasion.

Apart from that, its bendable tip and thixotropic behaviour makes it easy to access even posterior cavities and to control the placement in difficult areas. It comes in many shades, making it possible to make a truly aesthetic and inconspicuous restoration - which is requested increasingly often by patients.



Highly aesthetic cervical restoration with G-ænial Universal Injectable
Courtesy Dr Javier Tapia Guadix, Spain



Recall

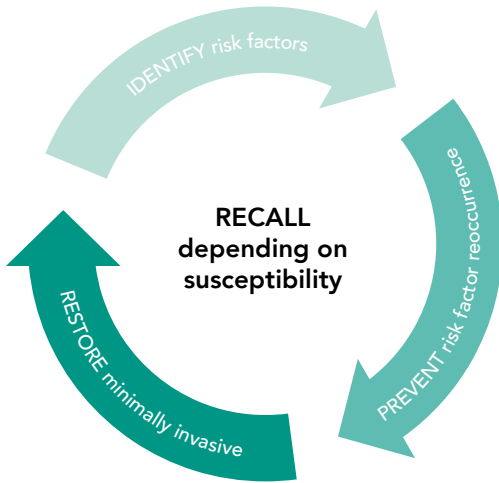
Follow-up regimen adjusted to response to treatment and caries risk

Periodic risk assessment should be regarded as routine for all dental patients. Preventive measures for root caries might be considered to have a better long-term prognosis than restorative treatments.

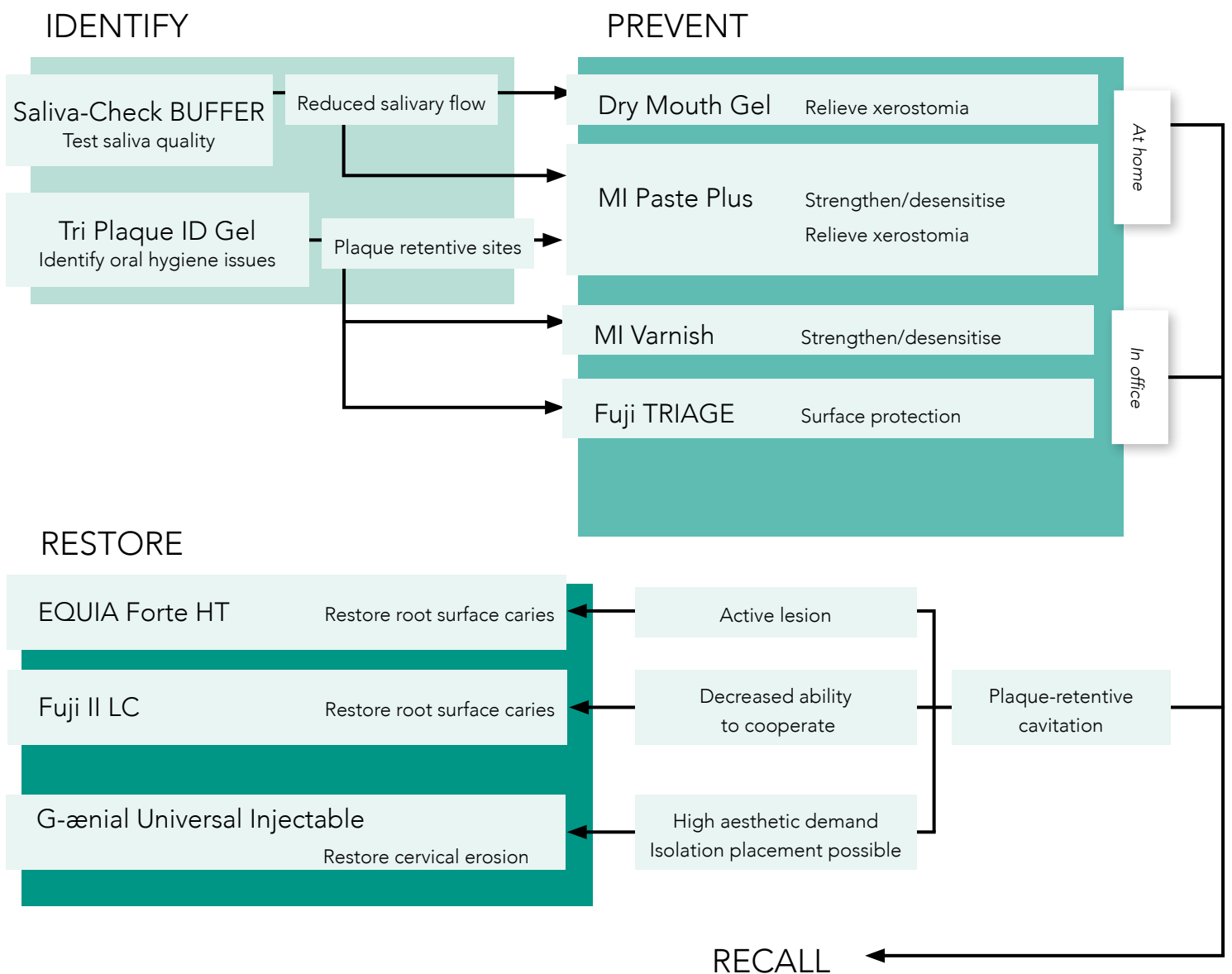
However, cavitated root caries are less likely to reverse from active to inactive status compared to non-cavitated lesions, so restoration is required in this case.

Minimum Intervention Treatment Plan for root caries

A framework for patient-centred treatment



It is essential to adapt the treatment of older people to the individual patient's conditions. The schedule below will make it easier to select the necessary interventions. It also shows which products from GC are especially suited for each individualised treatment plan.



Root caries treatment

MI TREATMENT SOLUTIONS from GC



SCAN FOR MORE INFORMATION



GC Tri Plaque ID Gel

Three-tone plaque disclosing gel



Saliva-Check BUFFER

In-office test to evaluate quality of saliva



GC MI Paste Plus

Bio-available calcium and phosphate, with fluoride



MI Varnish

Enhanced fluoride varnish treatment with bio-available calcium and phosphate



GC Fuji TRIAGE

Radiopaque glass ionomer surface protection material



GC Fuji II LC

Light cured glass ionomer restorative



EQUIA Forte HT

Bulk-fill glass hybrid long-term restorative system



G-aenial Universal Injectable

High-strength restorative composite

For ordering information, please check our online catalogue.

G-aenial Universal Injectable, GC Tri Plaque ID Gel, GC MI Paste Plus, MI Varnish, GC Fuji, GC Fuji TRIAGE and EQUIA Forte are trademarks from GC.

RECALDENT and RECALDENT logo are trademarks of Mondelēz International group used under license.

1. Berkey D, Berg R. Geriatric oral health issues in the United States. *Int Dent J* 2001; 51:254-264.
2. Baysan A. Consensus on root caries. 2022; <https://orca-caries-research.org/>
3. Chalmers JM. Minimal Intervention Dentistry: Part 1. Strategies for addressing the new caries challenge in older patients. *J Can Dent Assoc* 2006;72(5):427-433.
4. Hay KD, Morton RP. The efficacy of casein phosphoprotein-calcium triphosphate complex (DC-CP) [Dentalac] as a mouth moisturizer in patients with severe xerostomia. *N Z Dent J* 2003; 99(2):46-8.
5. Reynolds EC, Walsh LJ. Additional aids to the remineralisation of tooth structure. In: Mount GJ, Hume WR, editors. Sandgate (Qld): Preservation and restoration of tooth structure. Knowledge Books and Software 2005; p. 111-118.
6. Chalmers JM. Minimal Intervention Dentistry: Part 2. Strategies for addressing restorative challenges in older patients. *J Can Dent Assoc* 2006;72(5):435-440.
7. Schwendicke F, Gostemeyer G, Blunck U, Paris S, Hsu LY, Tu YK. Directly Placed Restorative Materials: Review and Network Meta-analysis. *J Dent Res*. 2016;95(6):613-22.
8. Schwendicke F, Müller A, Seifert T, Jeggler-Engbert LM, Paris S, Gostemeyer G. Glass hybrid versus composite for non-carious cervical lesions: Survival, restoration quality and costs in randomized controlled trial after 3 years. *J Dent*. 2021; 110:103689.
9. Schwendicke F, Gomez Rossi J, Krois J, Basso M, Peric T, Turkun LS, Miletić I. Cost-effectiveness of glass hybrid versus composite in a multi-country randomized trial. *J Dent*. 2021;107:103614.
10. da Mata C, McKenna G, Anweigi L, Hayes M, Cronin M, Woods N, O'Mahony D, Allen PF. An RCT of atraumatic restorative treatment for older adults: 5 year results. *J Dent*. 2019;83:95-99.

GC EUROPE N.V.

Head Office
Researchpark,
Haasrode-Leuven 1240
Interleuvenlaan 33, B-3001 Leuven
Tel. +32 16 74 10 00
Fax. +32 16 40 48 32
info.gce@gc.dental
<https://www.gc.dental/europe>

GC UNITED KINGDOM Ltd.

Coopers Court Newport Pagnell
Buckinghamshire
MK16 8JS
United Kingdom
Tel. +44 1908 218 999
Fax. +44 1908 218 900
info.uk@gc.dental
<https://www.gc.dental/europe/en-GB>