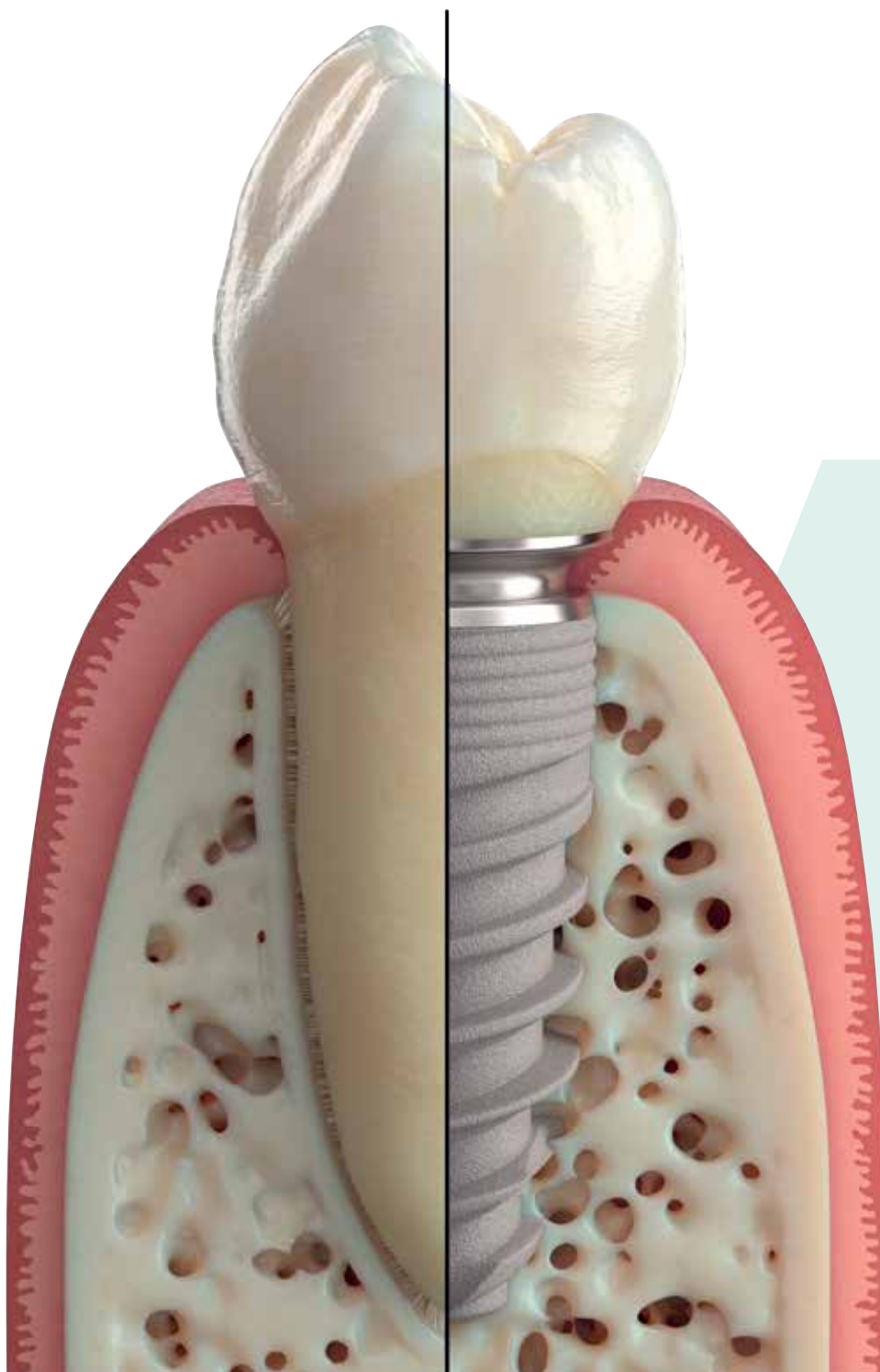

Implant Literature Compendium

GC Tech.Europe

MAY 2020

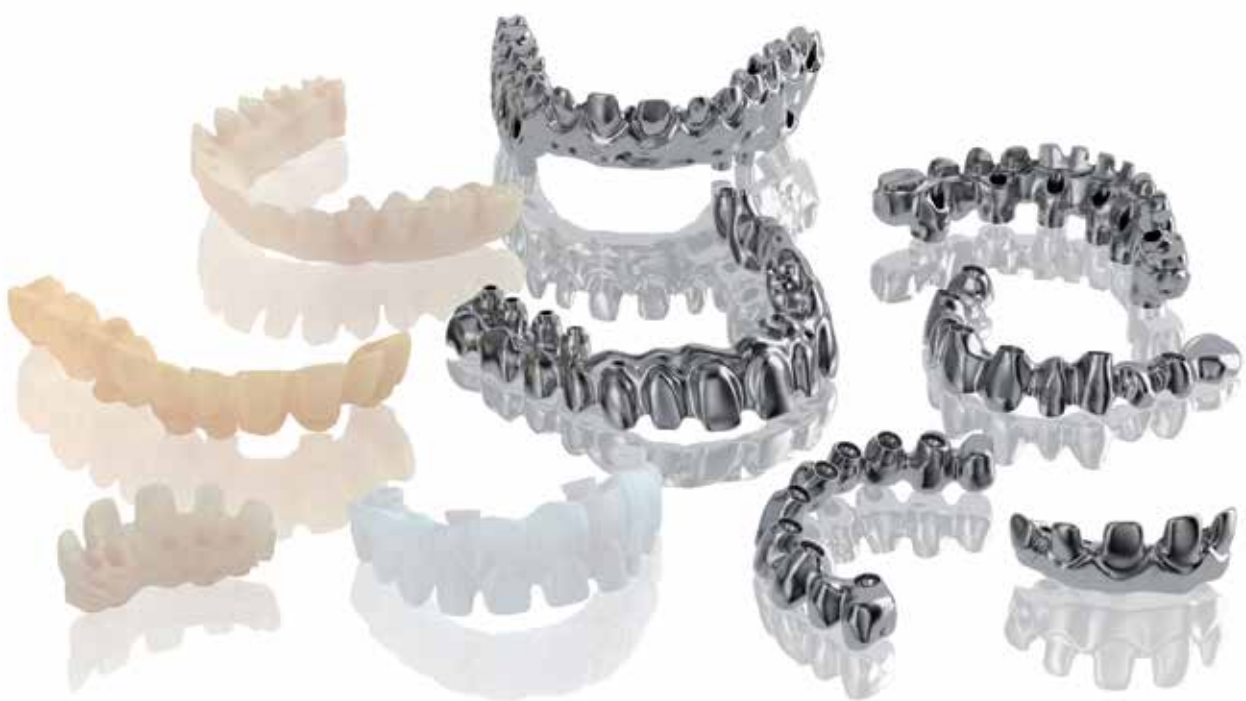



Reliable roots
from GC

Table of Contents

	Page
Full arch implant rehabilitation: a case report By Dr. David Garcia Baeza, Spain	5
Managing congenitally missing lateral incisors with implants The key factors to reach an excellent result By Dr. Miguel A Iglesia Puig, Spain	15
The challenge of replacing adjacent incisors By Dr. Cyril Gaillard, France	22
Implant shape and immediate loading: the Aadva solutions By Dr. Matteo Basso and Dr. Arturo Dian, Italy	29
Single tooth replacement in the aesthetic zone: contribution of the socket preservation technique to a durable end result By Dr. Alex Dagba, Dr. Romy Makhoul and Dr. Julien Mourlaas, France	35



Full arch implant rehabilitation: a case report



Dr. David Garcia-Baeza obtained his degree in dentistry at the European University of Madrid (EUM) in 2002. In 2006 he obtained the certification in implant and oral rehabilitation, also from EUM. He now runs a private practice at the CIMA center in Madrid, Spain, which is dedicated to aesthetics, restorative dentistry and implants. He is an Associate Professor in the Department of Periodontology at UEM and Assistant Professor in the Department of Aesthetic Dentistry at the Complutense University of Madrid. He is also member of the EAO (European Association of Osteointegration), SEPES (Spanish Society of Prosthodontics) and SEPA (Spanish Society of Periodontology). He has several publications in international journals and has given many national and international lectures on aesthetic and restorative dentistry.

By **Dr. David Garcia Baeza**, Spain

Partial or total loss of teeth not only affects facial aesthetics but also vital functions such as chewing and phonation. In this case, an implant-supported restoration is a good alternative to conventional full prostheses for patients with edentulism. The use of implants considerably improves the retention of a prosthesis and its functionality, thereby improving the patient's quality of life.

Full arch implant rehabilitation: a case report

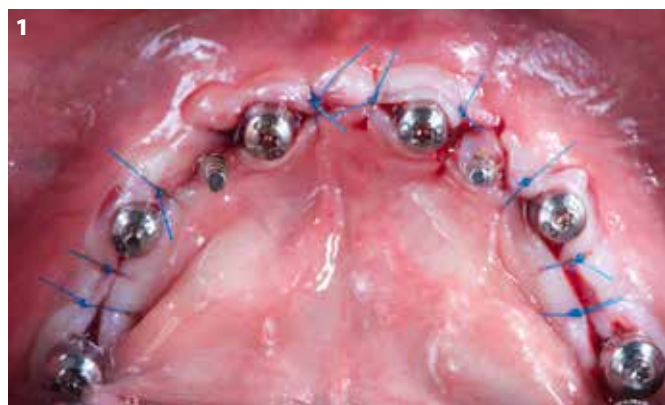
Prosthetic treatments of the edentulous jaw with dental implants are divided into two categories: fixed and removable restorations¹.

The factors that determine the type of implant-supported restoration for a complete edentulous patient are the amount of space from the bone to the occlusal plane (prosthetic space) and the lip support. When the space available for the prosthesis is less than 10 mm and there is lip support, a fixed porcelain-to-metal restoration is advisable. When there is more than 15 mm of prosthetic space and absence of lip support due to bone resorption, an implant-supported overdenture restoration is recommended, which will give that lip support not provided by the bony structures of the patient¹. The patient can remove the overdenture for cleaning and maintenance, since the space underneath the prosthesis is not directly accessible with the prosthesis in place.

However, when the prosthetic space is between 11 mm and 15 mm, and the bone structures provide sufficient lip support, a hybrid prosthesis can be considered.

A hybrid prosthesis consists of a cast metal framework covered by acrylic, which supports artificial teeth. The original design of the hybrid prosthesis developed by Swedish researchers using the two-stage endosseous implant system developed by Brånemark. The prosthesis consisted of a gold alloy framework attached to the copings of the implants, and on this framework conventional acrylic resin denture teeth were secured with acrylic resin². Zarb et al. described the treatment of severely resorbed complete edentulous maxillae with a hybrid prosthesis using a metallic structure with acrylic artificial teeth, with prosthetic spaces larger than 15mm³.

An incorrect adaptation between metal structures and implants can cause bone loss and failure of



osseointegration, and this is clinically decisive. It is generally accepted in literature that passive settlement of a prosthesis is required for maintenance and long-term success of an implant treatment. In addition, the literature has implied that incorrect adaptation of metal may cause mechanical and biological complications. The loosening of both the prosthesis and the abutment screws and even the fracture of different system components have been attributed to the lack of support and maladaptation of the prosthesis.

A 68-year-old patient consulted us with a complete upper mucosal-supported denture, with which he was relatively comfortable, and his own teeth on the lower arch. However, the remaining natural dentition suffered from very advanced periodontal disease with attachment loss of more than 80%; these teeth had Class II and III mobility, which made it very difficult to chew.

The proposed treatment plan for the patient was to extract the lower teeth and rehabilitate the lower arch using implants and a fixed prosthesis to maintain the same comfort as with his natural teeth, and for the upper arch to replace the full denture.

Normally, when teeth are extracted from a complete arch and an immediate restoration is placed, it creates a problem





Fig. 3: Frontal view. Patient smile.



Fig. 4: Frontal view. Patient initial picture.

of adaptation for the patient, especially in the lower arch area. To help the patient during this period of healing and osseointegration of the implants, two provisional implants were placed.

Once the extractions were healed, 6 Aadva Tapered Regular Implants 4x10 mm were placed, at the position of molars, first bicuspid and anterior incisors. The bone quality and quantity were good, and once the expected osseointegration time had passed, healing abutments were placed. In this case, two abutment diameters were used, narrower (SR Abutment 3.8 x 2 mm) for the incisor and bicuspid areas where there is less inserted gum tissue and wider (SR Abutment 4.3 x 2 mm) in the posterior area.

After this second phase, there was a waiting period for the tissues to heal prior to the start of the prosthetic phase. Therefore, an impression was taken with closed tray copings, which is very simple but does not give a very exact replica; This was used to make a metal rigid impression tray that was secured with plaster to only one of the implants.

Once placed in the mouth, open tray copings were then used and they were splinted to the structure with a special plaster mixture; once this had set, everything was registered with a vinyl polysiloxane impression paste. This technique

gives a very accurate master cast, so a very good fit was ensured.

Once the final model with the different analogs was ready, the planning started. First, the old complete upper denture was analysed. In this type of cases it is very useful to do a lateral analysis. We placed a narrow lead foil strip on the upper and lower central incisor before photographs and X-rays were taken. This served as a reference for the relationship between the position of the anterior teeth and the bone.

With the lateral X-rays, the positioning of the transitional abutments can be seen; this is very important since all the manipulation from the different tests that need to be done will be carried out far from the head of the implant.

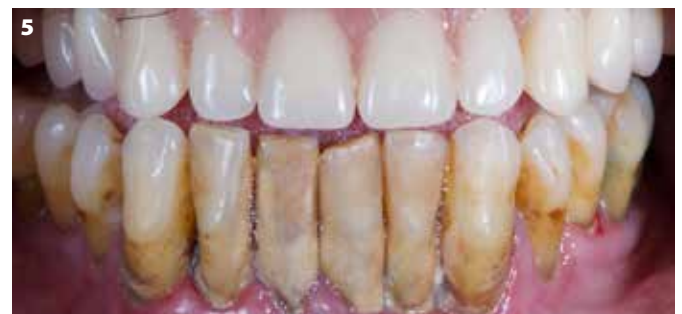

Fig. 5: Initial situation. Intraoral view.

Full arch implant rehabilitation: a case report

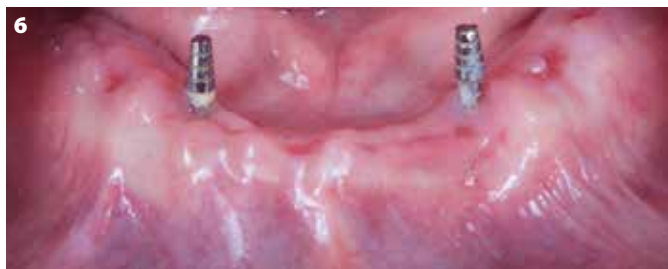

Fig. 6: After extractions. Frontal view.

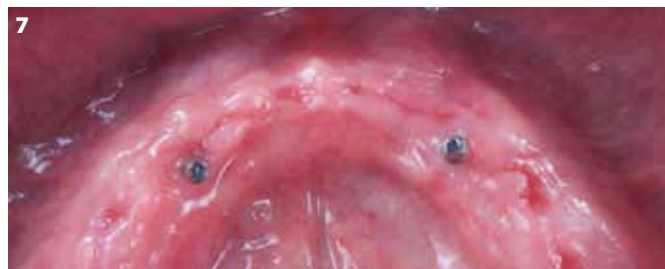

Fig. 7: After extractions. Occlusal view.

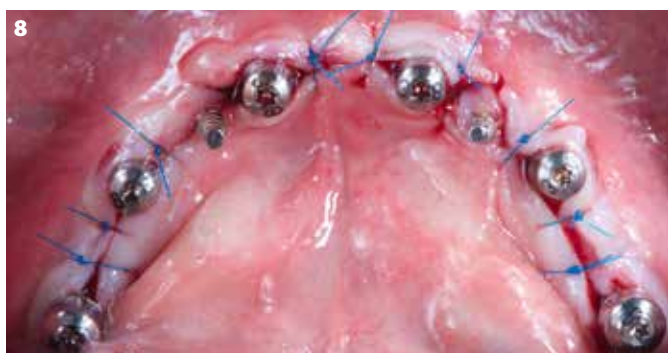

Fig. 8: Healing Abutments. Occlusal view.

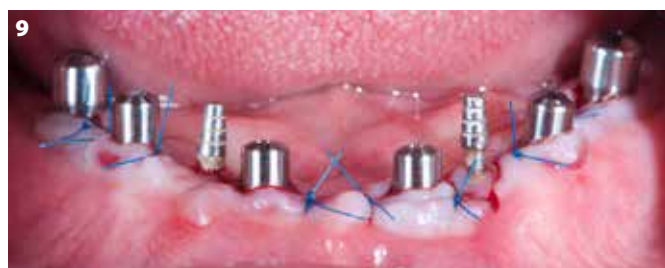

Fig. 9: Healing Abutments. Frontal view.

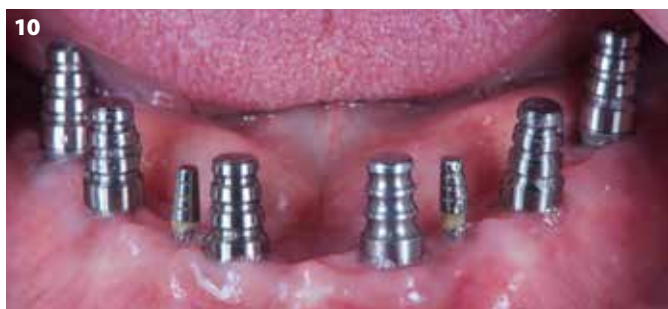

Fig. 10: Closed tray coping impressions.

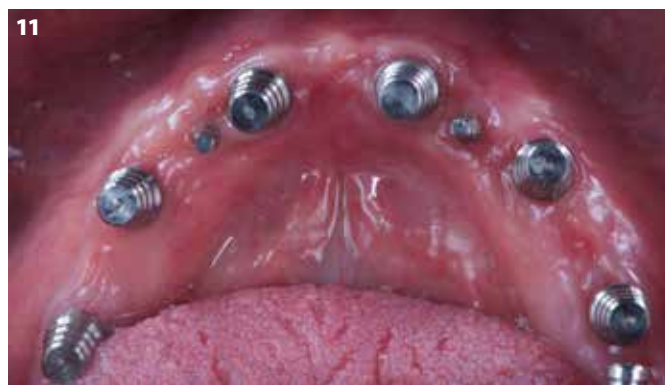

Fig. 11: Closed tray coping impressions. Occlusal view.

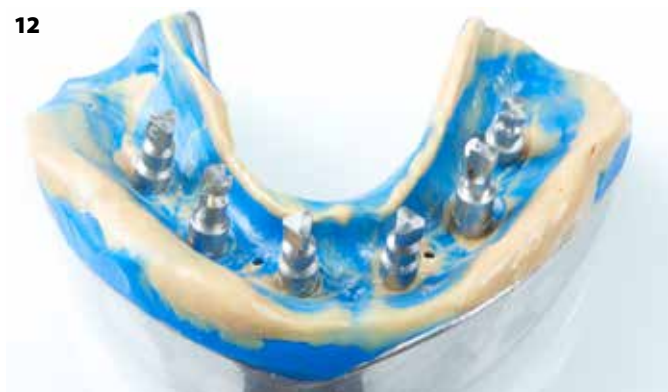


Fig. 12: Preliminary impression.

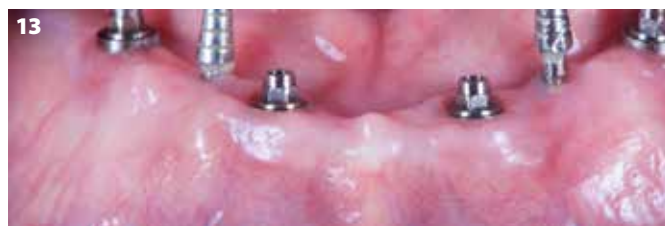

Fig. 13: SR abutments at gingival level.

Once the fulcrum point and inclination of the upper incisor for lip support were determined, we could start to design the new upper arch, giving the patient a new occlusal plane and a new incisor position. The Fox plane helped us to obtain the correct plane and we used the Kois Bow as the craniomaxillary reference.

Once the models were placed in the articulator and adjusted to the parameters from the patient, the laboratory technician created a wax-up for both the upper and lower arches so the correct fit could be assessed, including the patient's occlusion and aesthetics.

As the images show, the upper arch was narrower than the lower one because those teeth were lost much earlier, which means that for a correct functioning of the complete upper prosthesis while chewing, the posterior sectors had to be placed at a crossbite. This way, the force will act on the alveolar bone ridge when chewing food and will not cause displacement of the prosthesis.

Once confirmed that everything worked properly, the next step was constructing the metal structure based on the wax-up design. This was once again checked with the teeth in position as a last confirmation prior to the final

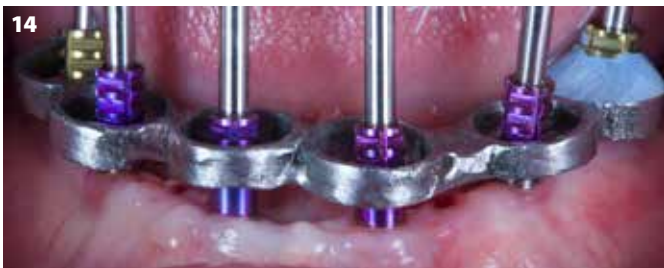

Fig. 14: Rigid Metal Tray Impresion.



Fig. 15: Rigid Metal Tray Impresion with plastic dam.

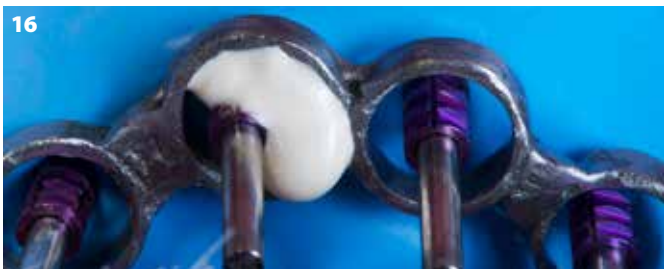

Fig. 16: Fixing with plaster.

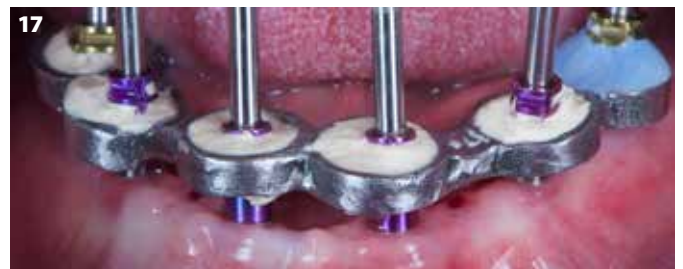

Fig. 17: First step. Final impresion.

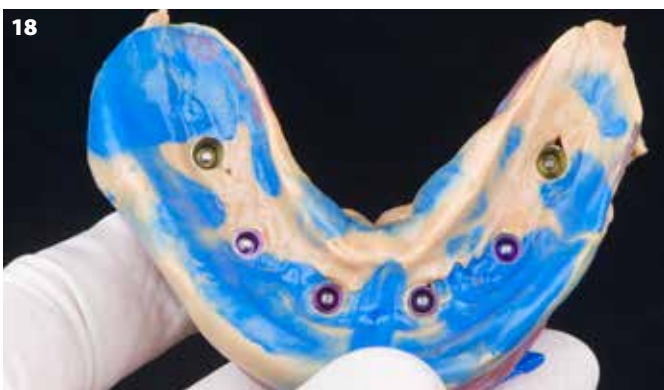

Fig. 18: Final impresion.

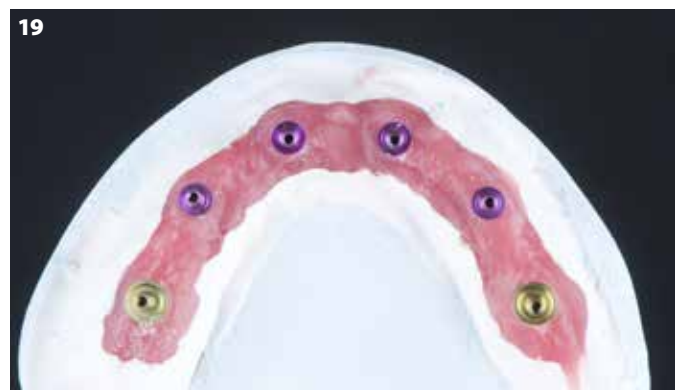

Fig. 19: Master Model.

Full arch implant rehabilitation: a case report

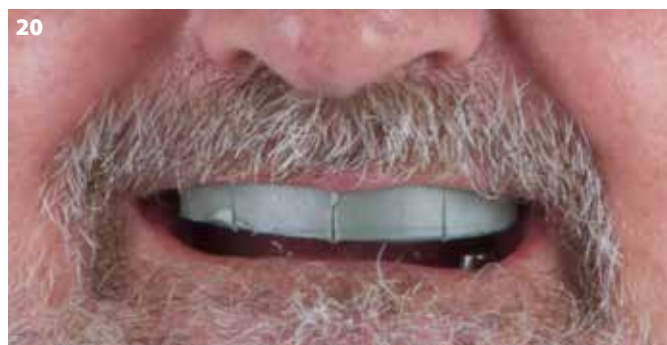

Fig. 20: Wax test. Smile parameters.



Fig. 21: Fox plane test.

manufacturing. At that time, confirmation of the modifications made could be verified by using the lead foil strip, as well as confirmation of the occlusion.

That was the moment when the final prostheses were made; the upper one was made as wide as possible in the



Fig. 22: Panadent Articulator phase.

posterior area to retrieve maximum stability, and the lower one was placed on implants. It was fit in the mouth and small adjustments had to be made to correct the small misalignments that normally occur in manufacturing.

The treatment of a complete edentulous patient using oral rehabilitation on implants begins by discussing treatment expectations and a meticulous intraoral and extraoral examination, following a systematic workflow to help in the diagnosis. This includes studying photographs and X-rays, which have evolved remarkably in recent times; analysing models on a semi-adjustable articulator and following a protocol to select the proper prosthetic rehabilitation on implants, choosing from overdentures, hybrid prostheses or fixed prostheses.

Implant-supported hybrid prosthesis can be an alternative treatment procedure when a fixed restoration of porcelain metal does not meet a patient's requirements for aesthetics, good phonetics, proper oral hygiene and oral comfort^{11,12}.

Brida et al. proposed an edentulous patient classification system for implant-supported fixed prosthesis, classifying them into four types according to the following factors:

- a) amount of tissue loss
 - b) position of the anterior teeth in relation to the location of the residual ridge
 - c) lip support
 - d) smile line
 - e) need for prosthetic material for gingiva color (pink acrylic)
- Class I includes patients who require gingiva-colored prosthetic material such as pink acrylic to obtain aesthetic

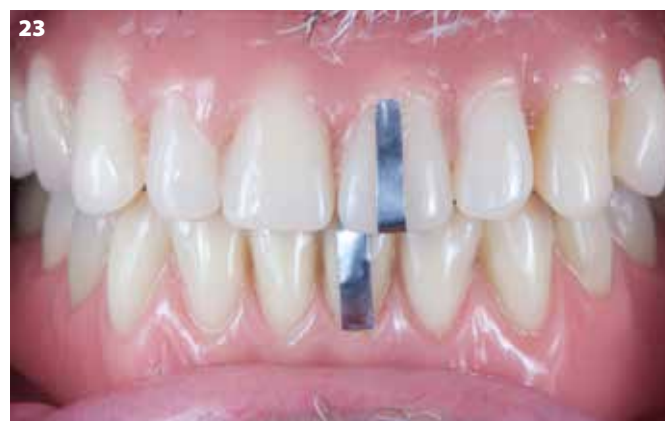

Fig. 23: Lead foil on the old denture for X-ray evaluation.

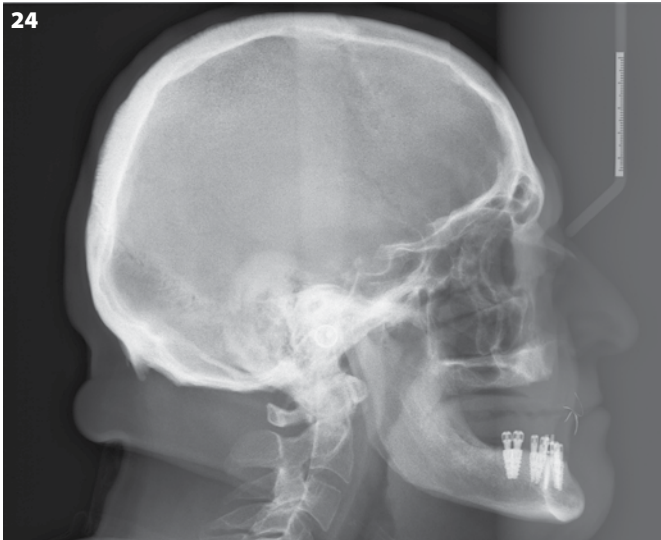

Fig. 24: Lateral X-ray.

tooth proportions and optimal prosthesis contour, providing an adequate lip support.

Class II is for patients who require pink acrylic only to obtain esthetic tooth proportions and for prosthesis contour. Lip support is not a consideration since the difference in lip projection with and without any prosthesis is generally insignificant.

Class III contains patients who do not require gingiva-colored prosthetic material.

Class IV is assigned to patients who may or may not require pink acrylic, depending on the result obtained after surgical intervention¹⁰.

Our case was classified as Class II.

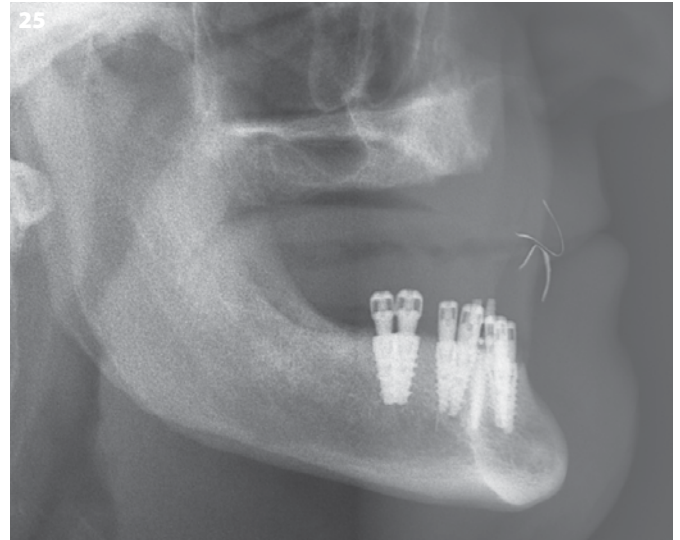


Fig. 25: Close up. Lateral X-ray.

Fabrication of hybrid dentures, in patients with adequate interocclusal space, provides the dentist with several advantages regarding the aesthetic appearance, including replacement and decrease of soft tissue support in the bulkiness of metal substructure and in the height of crowns

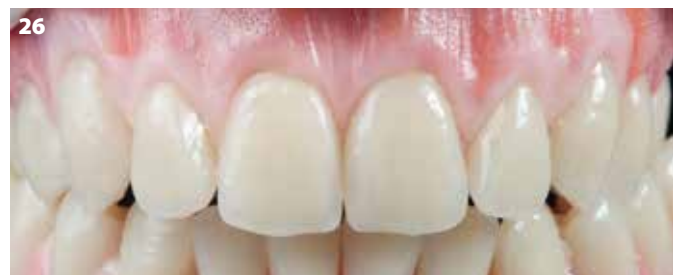

Fig. 26: Wax-up.

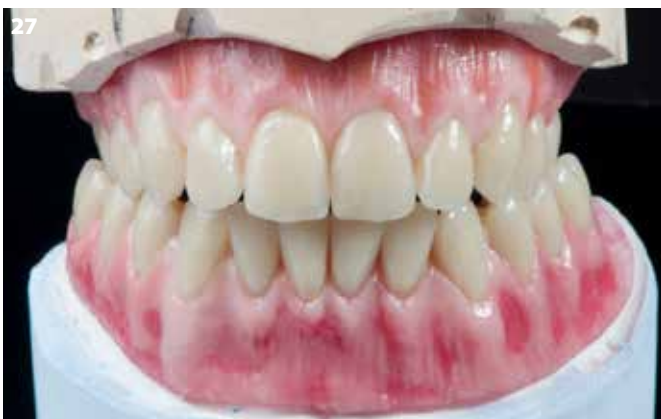

Fig. 27: Wax-up frontal view.

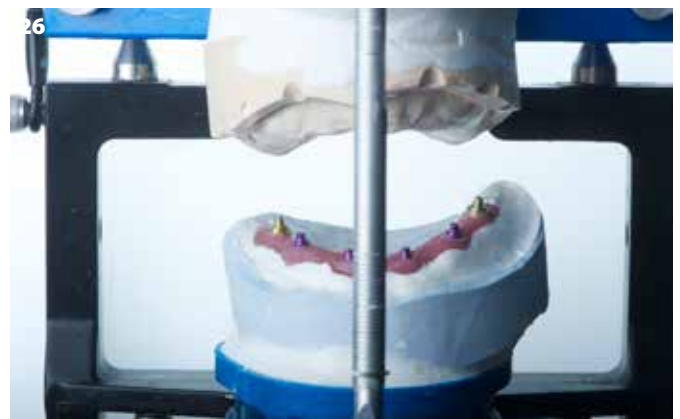

Fig. 28: Models in the correct position.

Full arch implant rehabilitation: a case report

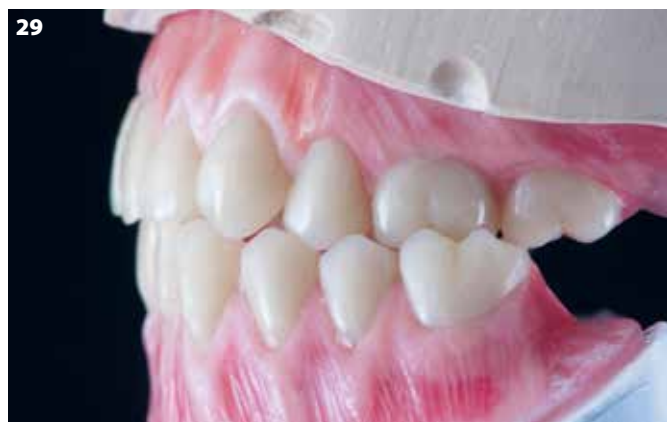

Fig. 29: Left view wax-up.

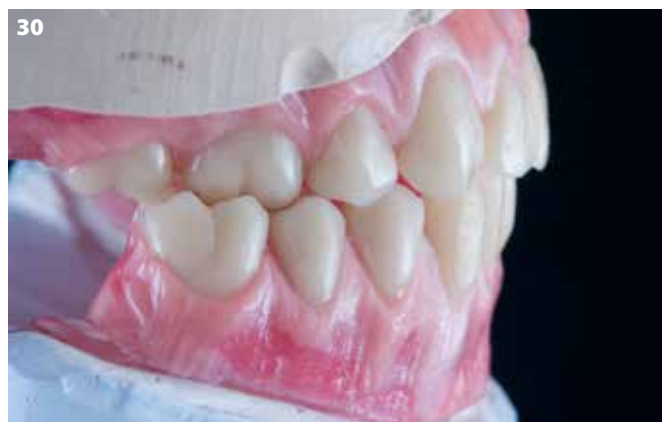

Fig. 30: Right view wax-up

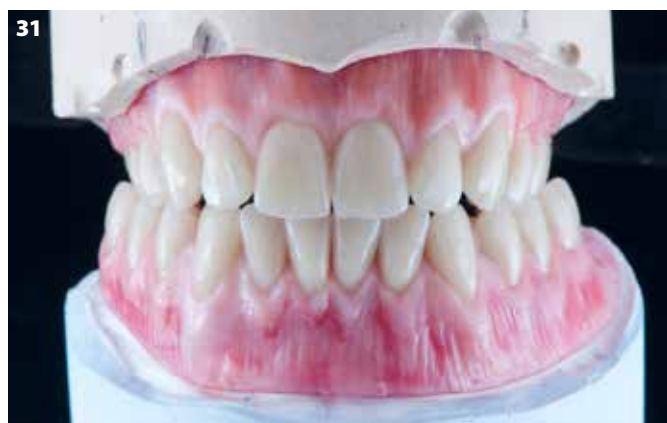

Fig. 31: Frontal view wax-up.

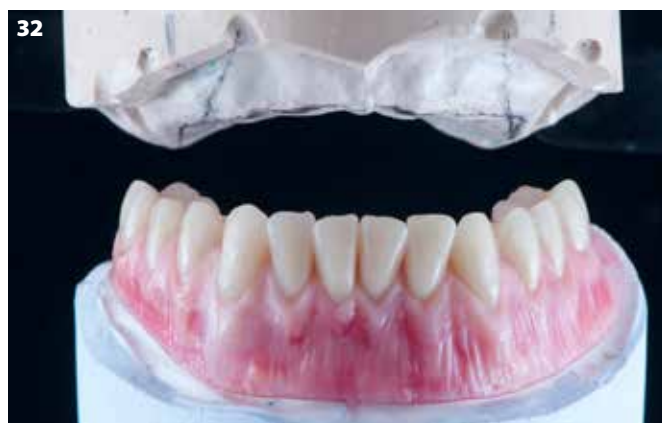

Fig. 32: Model in the articulator. Lower design.

compared to the metal supported porcelain prosthesis. In addition to these aesthetic advantages, hybrid prostheses work as shock absorbers, reducing load forces on implants¹³.

The success rate of implanted-supported hybrid prosthesis treatments is high, as demonstrated by a systematic review published in 2014, which included 18 studies for evaluation, high survival rates were found (5 to 10 years) from 93.3% to 100% for the prostheses and from 87.9% to 100% for the implants¹⁴.

In a retrospective study where the main complications after rehabilitation with an implant supported hybrid prosthesis were evaluated, it was observed that the main complication was mucositis that affected 24% of cases, followed by problems with the prosthetic screws in 13.7% of the cases, including, for example, thread wear or loss, and with the same frequency (13.7%) fracture of the prosthesis teeth or

prosthesis detachment. These problems were related to an incorrect record of vertical dimension, an inadequate occlusion or lack of passive adjustment of the metallic structure. Another problem encountered was the access to the entrance holes of the prosthetic screws (7.8%)¹⁵.

Making a lower jaw hybrid restoration is a good option for rehabilitation of edentulous maxilla, and it should be considered as a treatment option when evaluating a patient as it improves aesthetics, functionality, and proprioception; it is easy to clean, requires less prosthetic maintenance, can be removed at any time and repaired at a very low price.

REFERENCES

1. Misch CE. Contemporary implant dentistry. 3ra. Edición. St. Louis, Missouri: Mosby Elsevier, 2008.
2. Gonzales J. The evolution of dental materials for hybrid prosthesis. Open Dent J, 2014; 8: 85-94.

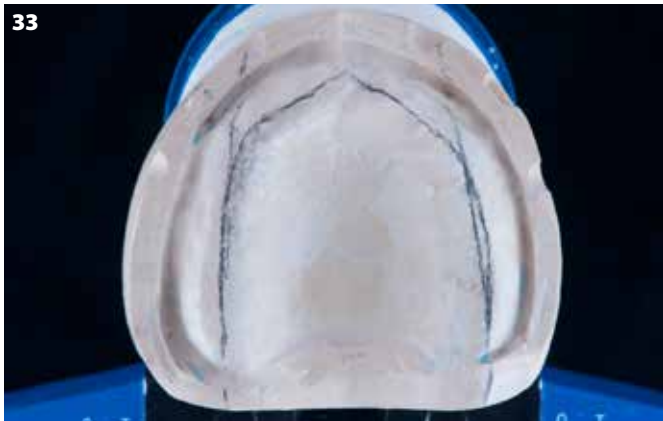


Fig. 33: Upper arch.

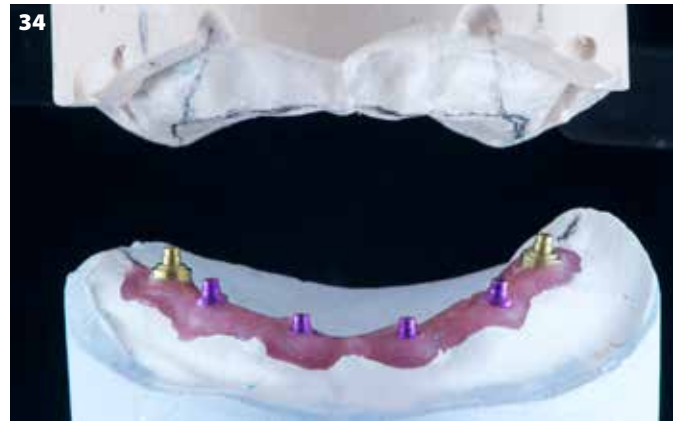

Fig. 34: Model in the articulator.

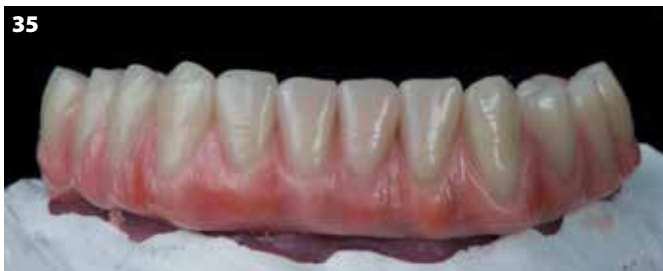

Fig. 35: Final wax-up Frontal view.

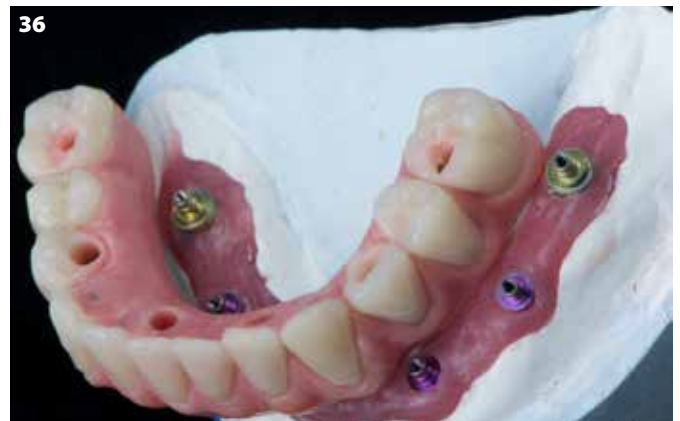

Fig. 36: Final wax-up.

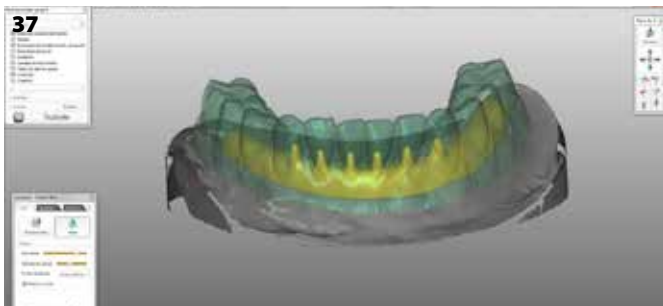


Fig. 37: Aadv software. Structure design.

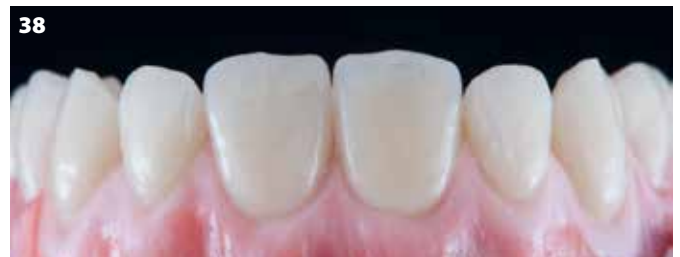

Fig. 38: Anterior view, final wax-up.

- Zarb GA. The longitudinal clinical efficacy of osseointegrated implants a 3 year report, *Int J Oral Maxillofac Surg*, 1987; 2: 91-100.
- Cobb G, Metcalf M, Parsell D. An alternative treatment method for a fixed-detachable prosthesis. A clinical report. *J Prosth Dent*, 2003; 89 (3): 239-243.
- Shibli JA, Piatelli A, Lezzi G. Effect of smoking on early bone healing around oxidized surfaces: a prospective, controlled study in humans jaw. *J Periodontol*, 2010; 81: 575-583.
- Bain C, Moy P. The association between the failure of dental implants and smoking. *Int J Oral Maxillofac Implants*, 1993; 8: 609-615.
- Grunder U, Gaberthuel T, Boitel N. Evaluating the clinical performance of the osseotite implant: Defining prosthetic predictability. *Compend Contin Educ Dent*, 1999; 20: 628-640.
- Bain C. Long-term satisfaction in dental implant patients. Toronto: 16th Scientific Meeting Academy of Osseointegration, 2001.
- Balarezo JA. Prótesis sobreimplantes en el edéntulo total: Planificación y elaboración. Lima, Perú: Editorial Savia, 2014.
- Brida A, Agar J. A classification system of patients for esthetic fixed implant-supported prostheses in the edentulous maxilla. *Compend Contin Educ Dent*, 2010; 31(5): 366-8.
- Tarnow DP, Emtiaz S, Classi A. Immediate loading of threaded implants at stage 1 surgery in edentulous arches: Ten consecutive case reports with 1- to 5-year data. *Int J Oral Maxillofac Implants*, 1997; 12(3): 319-2.
- Real-Osuna J, Almendros-Marqués N, Gay- Escoda C. Prevalence of complications after the oral rehabilitation with implant-supported hybrid prostheses. *Med Oral Patol Oral Cir Bucal*, 2012; 17 (1): 16-21.

Full arch implant rehabilitation: a case report

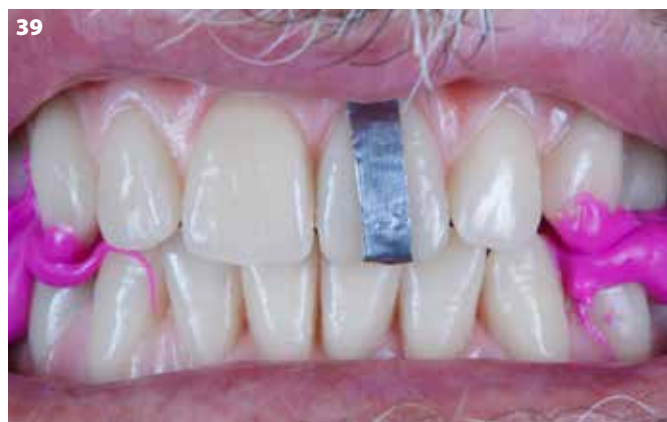

Fig. 39: Lead foil test for the new design, intraoral situation.

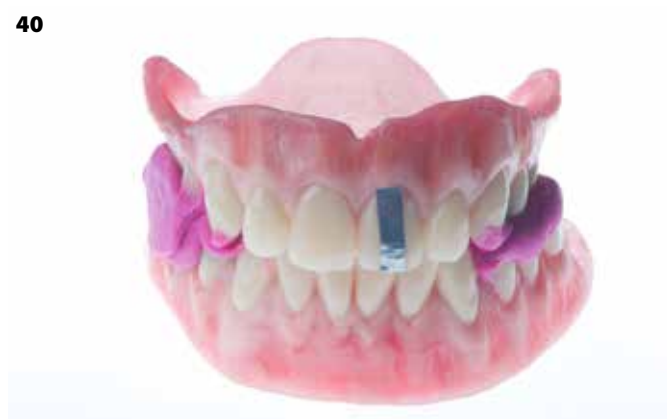

Fig. 40: Lead foil test for the new design.

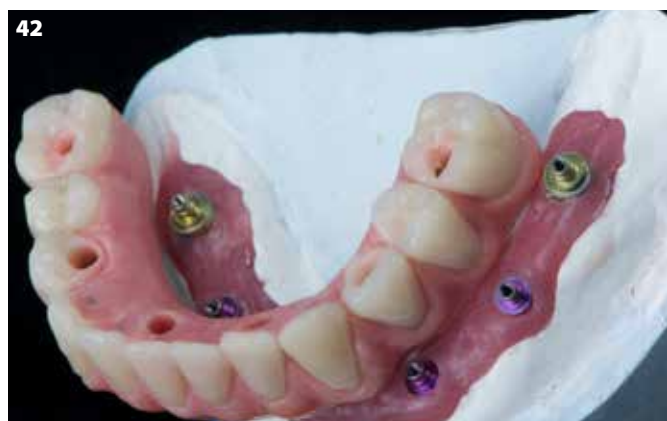

Fig. 42: Final restorations. Frontal view.

13. Qamheya AH, Yeniol S, Arisan V. Full Mouth Oral Rehabilitation by Maxillary Implant Supported Hybrid Denture Employing a Fiber Reinforced Material Instead of Conventional PMMA. *Case Rep Dent*, 2015; 841745.
14. Kwon T, Bain P, Levin L. Systematic review of short (5-10 years) and long-term (10 years or more) survival and success of full-arch fixed dental hybrid prostheses and supporting implants. *J Dent*, 2014; 42 (10): 1228-41.
15. Egilmez F, Ergun G, Cekic-Nagas I, Bozkaya S. Implant-supported hybrid prosthesis: Conventional treatment method for borderline cases. *Eur J Dent*, 2015; 9: 442-8.

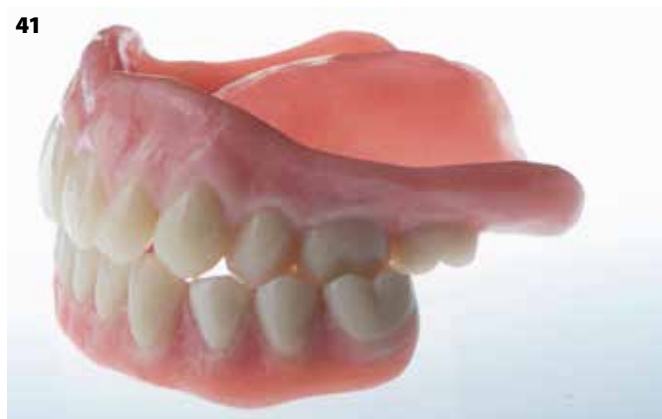

Fig. 41: Final restorations. Lateral view.

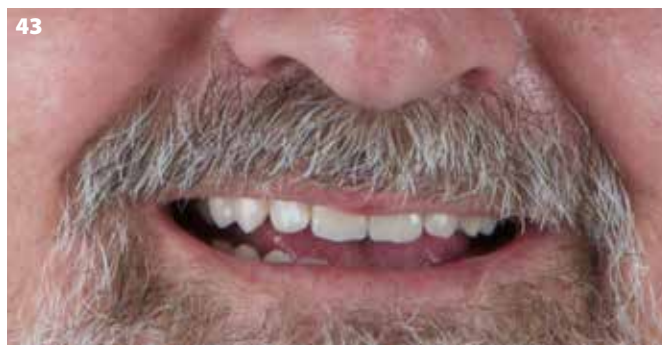

Fig. 43: Final smile.

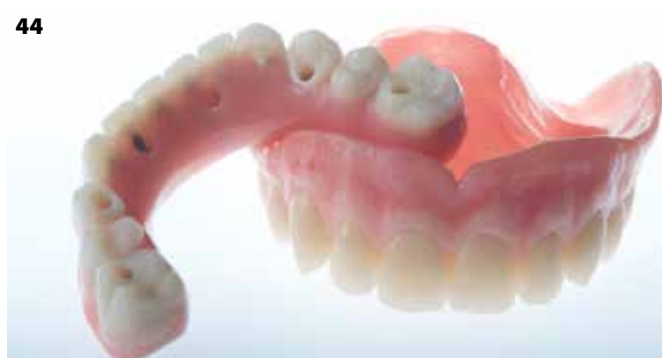

Fig. 44: Final restorations.

Managing congenitally missing lateral incisors with implants

The key factors to reach an excellent result

By Dr. Miguel A Iglesia Puig, Spain



Dr. Miguel A Iglesia Puig has a full-time private practice in Zaragoza, Spain. He has more than 23 years of practice in oral implantology and general dentistry, and more than 8 years of clinical experience with the Aadva GC Implant System. He obtained his Dental Degree as well as his Postgraduate Implant training and his PhD at the Basque Country University (UPV) in Bilbao (Spain).

Dr Iglesia has written over 40 scientific articles and 4 textbook chapters. In 2001, he received the Annual Award of the Spanish Society of Prosthodontics for the best original research study. Dr Iglesia serves on the Scientific Council of the Aragón Dental Association and he is part of the editorial board and the peer-review team of various international dental publications. Since 2010, he is an external consultant referee of The International Journal of Oral and Maxillofacial Implants.

Congenital missing teeth is a highly prevalent dental anomaly, with a 5.5% prevalence in permanent teeth, excluding third molars¹. Maxillary lateral incisors are one of the most affected teeth with agenesis. Besides an unfavourable appearance, patients with missing teeth in the anterior zone may suffer from malocclusion, periodontal damage, insufficient alveolar bone growth, reduced chewing ability and other problems².

Implant-supported single tooth restoration in the aesthetic area is currently a well-documented and predictable treatment option to replace a missing single tooth in this zone³. Cases of dental agenesis of anterior teeth are challenging, and many specific aspects have to be carefully evaluated. Patients usually need orthodontic treatment in order to correct the malocclusion resulting from this absence. A correct and meticulous diagnosis is mandatory to decide whether spaces closure and canine substitution⁴, or space

Managing congenitally missing lateral incisors with implants - The key factors to reach an excellent result

opening to create enough width for the restoration⁵, is the appropriate treatment plan. Biological aspects are also very important. Usually the present bone is poor in quality and quantity, and both have to be improved and corrected in the surgical phase. All the issues of an aesthetic case are also important to consider when restoring missing teeth: smile line, shape and size of adjacent teeth, soft tissue volume, periodontal biotype, need for temporisation, importance of flap design and surgical technique, aesthetic materials... always with a global vision on patient's health, function and smile.

The case presented brings together all this aspects, using the Aadva Implant System (GC Tech) and a milled zirconium abutment (GC Tech Milling Centre, Leuven, Belgium) covered with Initial ceramic (GC), highlighting the importance of a correct diagnosis, a careful and minimally invasive surgical approach, and a correct selection of materials.

CASE REPORT

A 29-year old male patient presented with agenesis of the right upper lateral incisor. Orthodontists decided to open the space to replace this missing tooth, and when the mesio-distal and inter-occlusal spaces were adequate to replace it (Figures 1-2), the patient was referred to us.

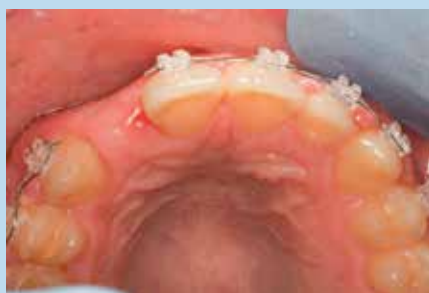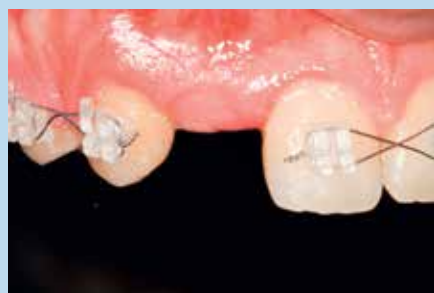After clinical, and radiographic examination (CBCT and periapical)

and diagnostic assessment (including casts), the therapeutic plan was drawn up including placement of a narrow diameter implant with delayed loading, a provisional implant-supported restoration after second-stage surgery, and a metal-free screw-retained esthetic implant definitive single crown. The CBCT diagnosis found enough bone availability in the coronal part of the future implant, but a concavity in the middle and apical zone of the buccal plate (Figure 3).

The patient had a low smile line and a thick periodontal biotype.

Implant surgery began with a crestal incision slightly deviating towards palatal, including intrasulcular in the distal part of the right upper central and mesial of the right upper canine, and avoiding vertical releasing incisions.

Bone was prepared carefully with a drilling sequence adapted to bone quantity and quality, with a non-



Figures 1-2: Preoperative frontal and occlusal view. Agenesis of the right upper lateral incisor.




Figure 3: CBCT: Sufficient bone in the coronal part, and a concavity in the middle and apical part.

Figure 4: Drilling sequence:

- a) Initial bur;
- b) 2 mm twist drill up to 7 mm length;
- c) 2 mm osteotome up to working length;
- d) 3 mm osteotome up to working length;
- e) Tapered implant drill narrow up to 12 mm.

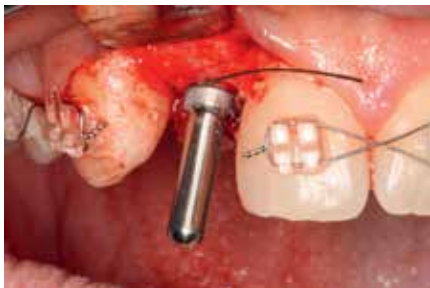
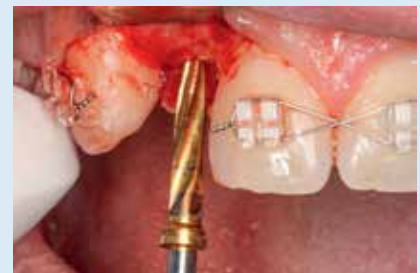
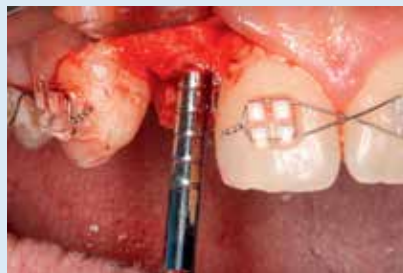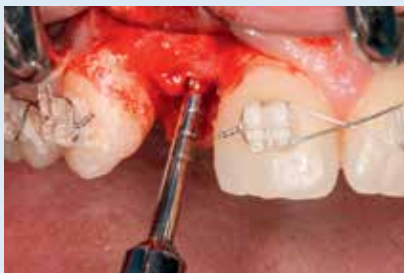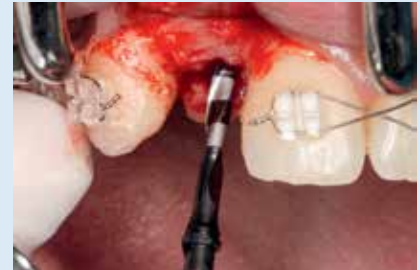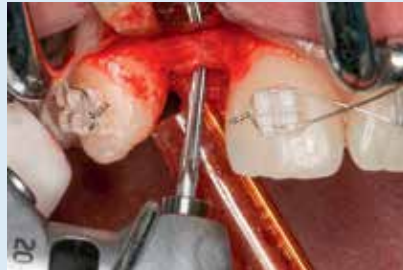Figure 5: Checking three-dimensional position of the future implant.

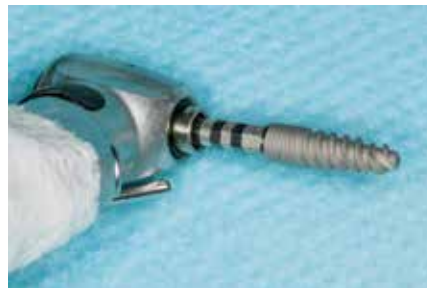

Figure 6: Aadva tapered implant narrow.

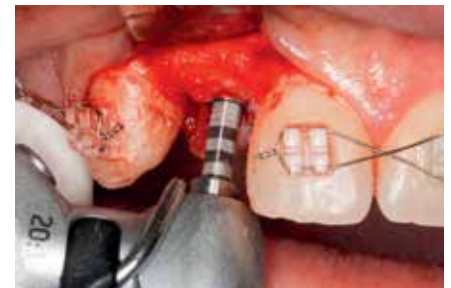

Figure 7: Implant insertion.

irrigation low-speed technique (50 rpm) and including the use of manual osteotomes between the uses of drills (Figure 4). Using osteotomes, the aim was to preserve as much as possible the low-density bone, compact it, and expand the buccal ridge in the middle and apical part⁶.

Implant site was slightly underprepared to ensure high implant stability, avoiding countersinking in order to engage as much of the crestal bone as possible and to avoid damaging of the cortical bone. When the bone was prepared

and the three-dimensional position of the future implant was checked with a direction and depth indicator (Figure 5), one rough-surfaced grade 5 titanium implant (12 mm tapered implant narrow, GC Implant Aadva) (Figure 6) was placed, according to the treatment planning with 35 N of torque (Figure 7). Adequate apicocoronal position was achieved (Figure 8) and confirmed with a manual insertion torque wrench, leaving as much width as possible in the buccal plate (Figure 9).

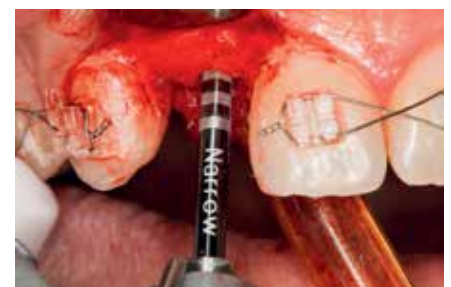

Figure 8: Adjustment of implant depth position with a manual insertion torque wrench: Apically there is 3 mm space between the implant platform and the cemento enamel junction of adjacent teeth.

Managing congenitally missing lateral incisors with implants - The key factors to reach an excellent result

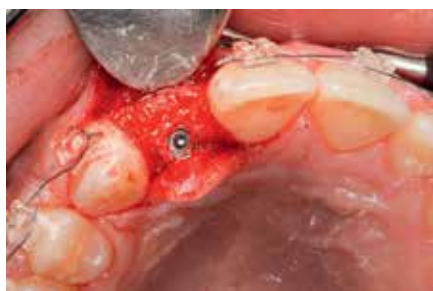

Figure 9: Occlusal view of the placed implant. Width of the buccal bone is 2.5 mm, which is important for long-term peri-implant tissues stability.

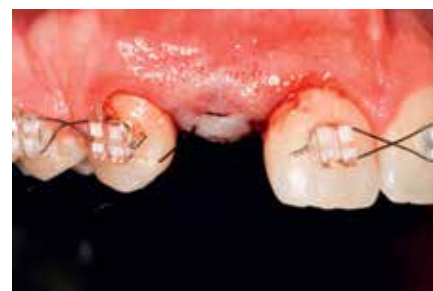
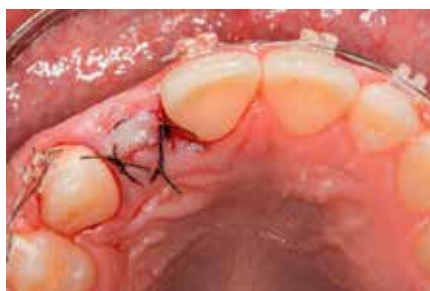
Figure 10: Wound sutures. a) Occlusal view; b) Buccal view

After suturing (Figure 10), an acrylic resin tooth was attached to the orthodontic wire as a provisional. After healing and a 3-month uneventful osseointegration period (Figure 11),

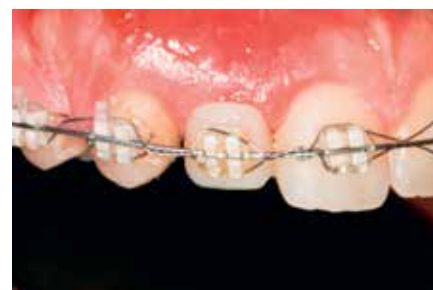
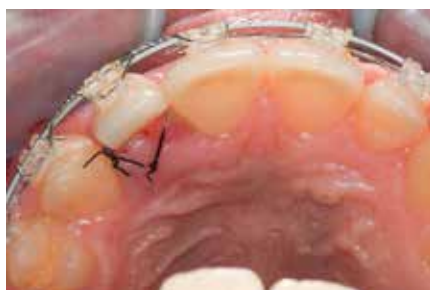
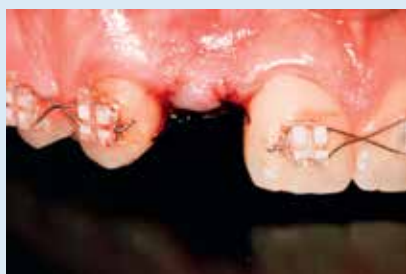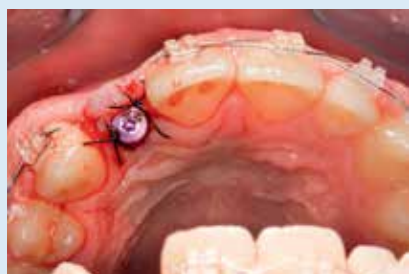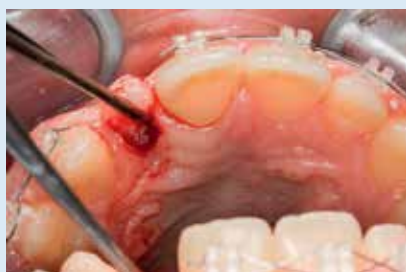Figure 11: One-week postop. a) Occlusal view; b) Buccal view.

Figure 12: Second-stage surgery with a minimally invasive approach. a) Incision; b) Occlusal view with healing abutment; c) Buccal view.



the implant was uncovered with a minimally invasive incision (Figure 12), and one day later, a screw-retained acrylic provisional was connected to the implant (Provi Abutment Hexed Narrow, GC Implant Aadva; Figure 13).

Subgingival emergency profile had a concave design in order to allow the soft tissue to adapt to it without pressure (Figure 14). The width of this provisional was the same as that of the upper left lateral

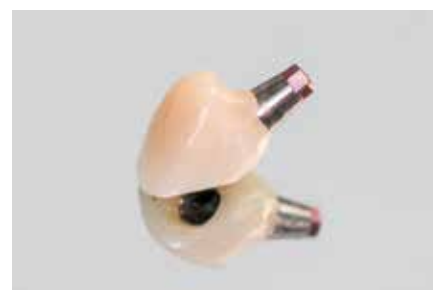

Figure 13: Screw-retained acrylic provisional crown. Concave emergency profile design.

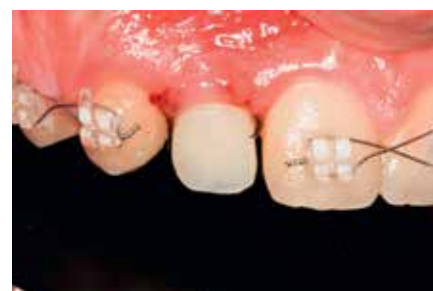

Figure 14: After placement of the acrylic provisional crown.

incisor, and mesio-distal small remaining spaces were closed with orthodontic treatment (Figure 15).

Soft tissues were healing and adapting to the provisional and the brackets were removed (Figure 16). The teeth were whitened by home bleaching during three weeks (Figure 17).

Figure 15. Orthodontic spaces closure. a) After 1 week; b) After 2 weeks; c) After 3 weeks.

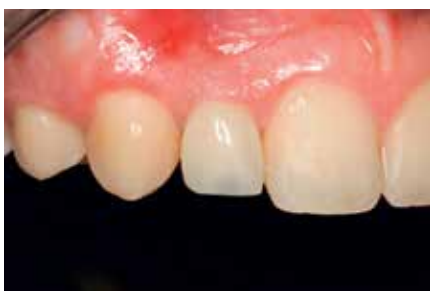
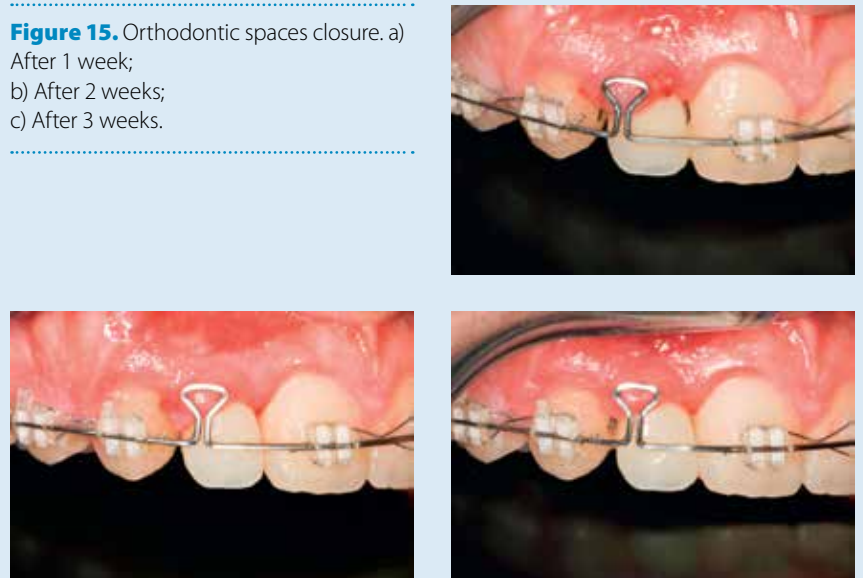
Figure 16. Soft tissues healing 3 months after second-stage surgery.

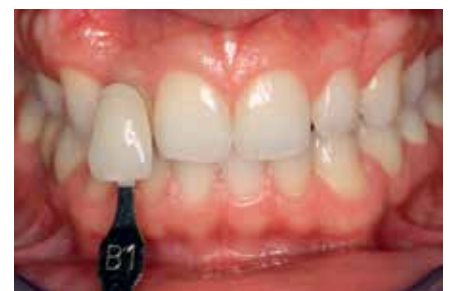
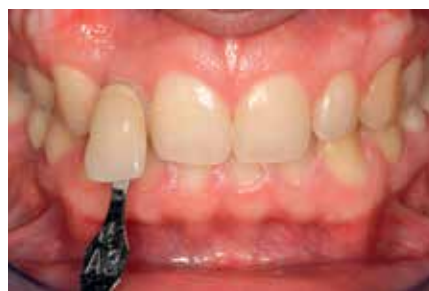
Figure 17. Home whitening treatment. a) Preoperative; b) Postoperative.

An individualised impression post copying the subgingival part of the provisional was prepared (Figure 18), and the final impression was made (Figures 19 to 21).

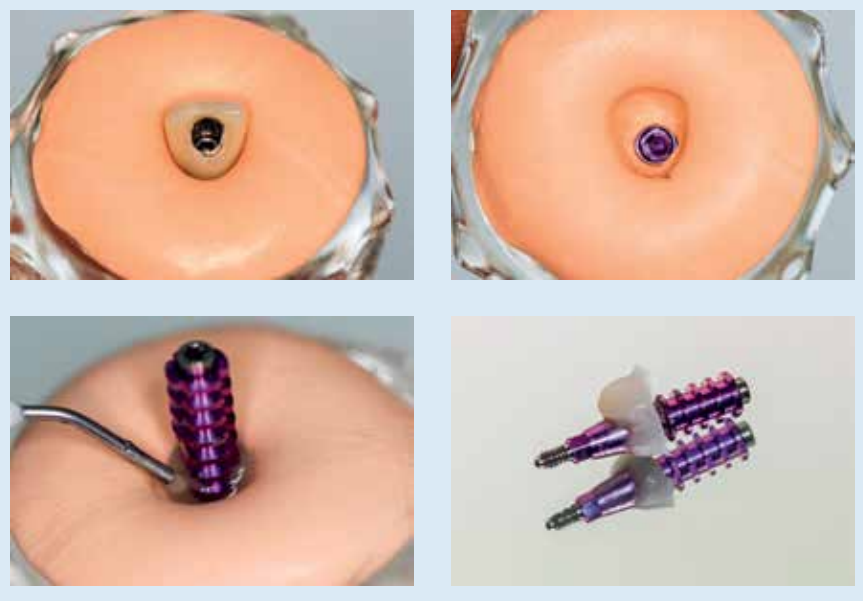


Figure 18 a-d. Preparation of an individualised impression post copying subgingival part of the provisional.

Managing congenitally missing lateral incisors with implants - The key factors to reach an excellent result

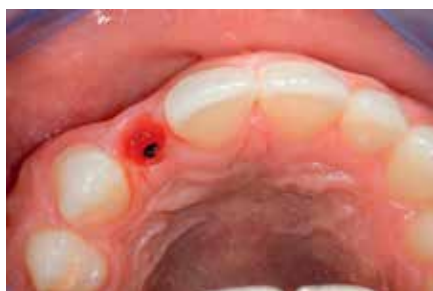

Figure 19. Emergency profile. Occlusal view prior final impression.

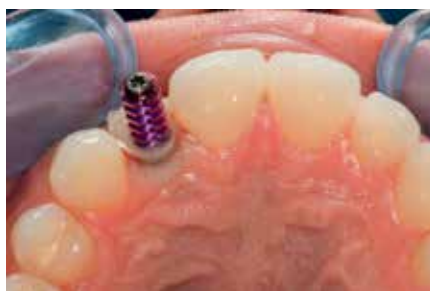

Figure 20. Individualised impression coping in place.

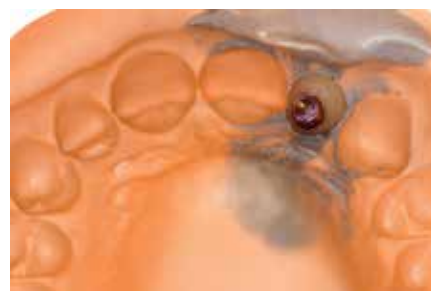
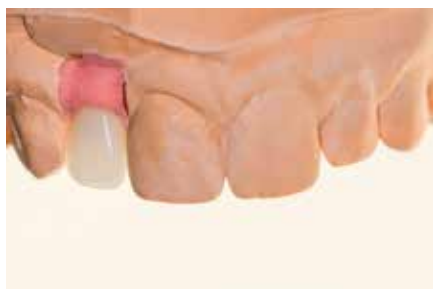
Figure 21. Final pick-up impression.



Figures 22-23. Screw-retained single-unit final restoration: individual zirconium CAD-CAM abutment covered with ceramic and cemented to a metallic base.



An individual zirconium CAD-CAM abutment (GC Tech Milling Centre) was covered with ceramic (Initial Ceramics, GC) and luted with a resin cement to a metallic base (Blend-/ Hybridabutment, GC Tech), providing a metal-free restoration that could perfectly integrate in the smile (Figures 22 and 23).

This final restoration was screwed on the implant (Figure 24).

The final restoration demonstrated excellent aesthetics and improved integration, shape and shade at the 3-year follow-up appointment (Figure 25).

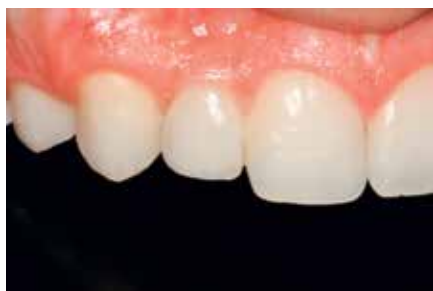

Figure 24. Final restoration screwed on the implant.

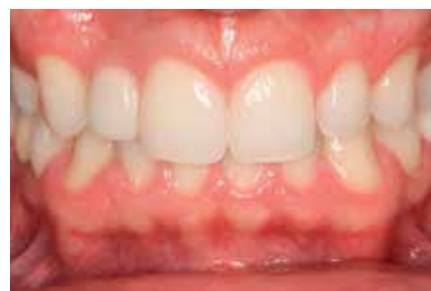
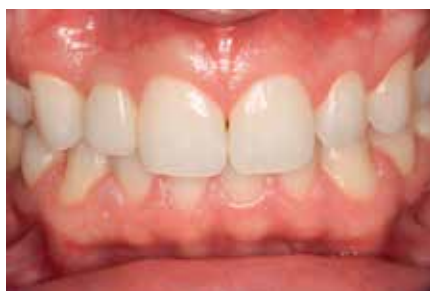
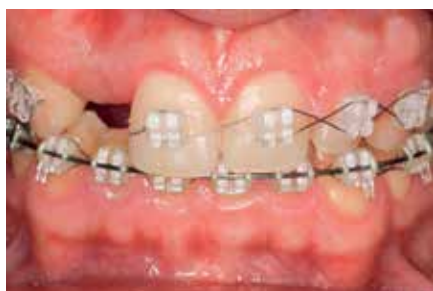Figure 25. Frontal views in occlusion. a) Preoperative; b) Postoperative; c) 3-year follow-up.

DISCUSSION

A correct diagnosis is crucial when restoring missing teeth in the aesthetic zone with implant-supported restorations. Analysing carefully and managing properly orthodontic, biologic and aesthetic aspects may lead to successful results. In this case some of these aspects were not favourable, like bone volume and quality. As the bone width was wide enough in the coronal part of the implant, and the patient had a low lip line and thick periodontal biotype, no bone volume augmentation was needed, and the use of osteotomes and a careful surgical technique were enough to solve it.

A minimally invasive surgical approach is mandatory in the anterior region, using conservative incisions in surgeries. Also low speed drilling sequence, infra-preparation and osteotomes were used in order to avoid over-preparation, overheating and to

minimise the destruction of the cancellous bone. To achieve implant stability, a proper implant design and minimal and precise manipulation is required.

The implant was placed while the patient was in orthodontic treatment, allowing attaching the immediate provisional to the wire, and facilitating the space closure when implant-retained provisional was connected. Evaluating the case as a whole is mandatory, because sometimes patients with dental agenesis have other dental anomalies in adjacent teeth. Those were not present in this case. Nevertheless, from the aesthetic point of view there was an unfavourable teeth colour, which was improved by tooth whitening treatment.

The use and selection of the adequate materials for the restoration, and a meticulous work by the lab technician are essential points to achieve

excellence. Computer aided design and manufacturing of the zirconia custom abutment, with the proper use of a ceramic coating worked with care, let the clinician get a successful and perfectly integrated metal-free restoration.

ACKNOWLEDGEMENTS

Work in an interdisciplinary way and in good harmony with orthodontists is always a pleasure. The author wants to acknowledge the orthodontic treatment done on this patient by Drs. Teresa Lorente, Carmen Lorente and Pedro Lorente (Lorente Ortodoncia, Zaragoza, Spain).

The author also wants to recognise the artistry of ceramist Beto Villanueva (Función y Estética Laboratorio Dental, Zaragoza, Spain), with whom it is always easy to discuss and to achieve excellent work.

REFERENCES

1. Polder BJ, et al. A meta-analysis of the prevalence of dental agenesis of permanent teeth. *Comm Dent Oral Epid* 2004; 32: 217-26.
2. Rakhshan V. Congenitally missing teeth (hypodontia): A review of the literature concerning the etiology, prevalence, risk factors, patterns and treatment. *Dent Res J* 2015; 12: 1-13.
3. den Hartog L, et al. Treatment outcome of immediate, early and conventional single-tooth implants in the aesthetic zone: a systematic review to survival, bone level, soft-tissue, aesthetics and patient satisfaction. *J Clin Period* 2008; 35: 1073-1086.
4. Zachrisson BU, et al. Congenitally missing maxillary lateral incisors: canine substitution. *Am J OrthodDentofacOrthoped* 2011; 139: 434-45.
5. Kinzer GA, et al. Managing congenitally missing lateral incisors. Part III: single-tooth implants. *J Esthet Rest Dent* 2005; 17: 202-10.
6. Summers RB. A new concept in maxillary implant surgery: the osteotome technique. *Compendium* 1994; 15: 152-6.



Dr. Cyril Gaillard graduated from the University of Bordeaux II in 1998, followed by numerous post-graduate training in aesthetic, implant and prosthetic rehabilitation in Europe, Canada and the USA. He is also the Founder and President of Global Advanced Dentistry (www.gad-center.com). He has authored numerous articles and lectures about aesthetics, full mouth rehabilitation, implants and function. He has a private practice at Bordeaux in implantology and aesthetic dentistry.
www.gad-center.com

The challenge of replacing adjacent incisors

By Dr. Cyril Gaillard, France

Replacing missing adjacent maxillary incisors is a very challenging procedure since aesthetic play a crucial role in this area. Gingival tissue preservation is a major factor, especially in young patients, where the maxillary lip line is usually higher and the gingiva is more apparent. Achieving an excellent papilla between the adjacent missing teeth when using implants is not easy. In addition, achieving ideal gingival margin levels may be a problem as well, depending upon the amount of bone loss that occurred when the teeth were lost.

Case report

A 26-year old female patient visited the clinic because she was dissatisfied with the tooth-supported PFM-bridge in the maxillary zone. The narrow space between the two abutment teeth was closed by one pontic causing an apparent asymmetry in the smile (Figs. 1-3).

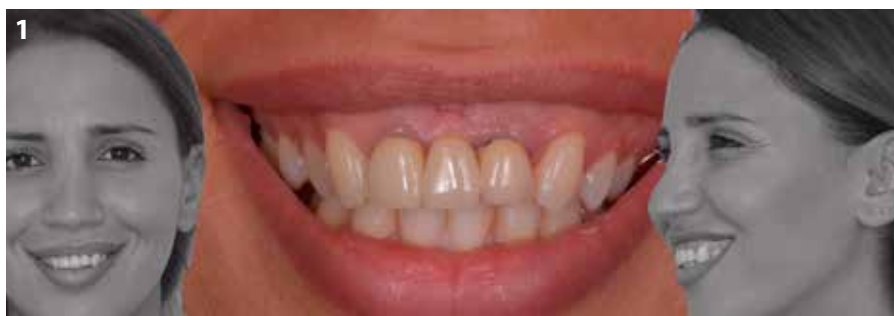

Fig. 1: preoperative extraoral view

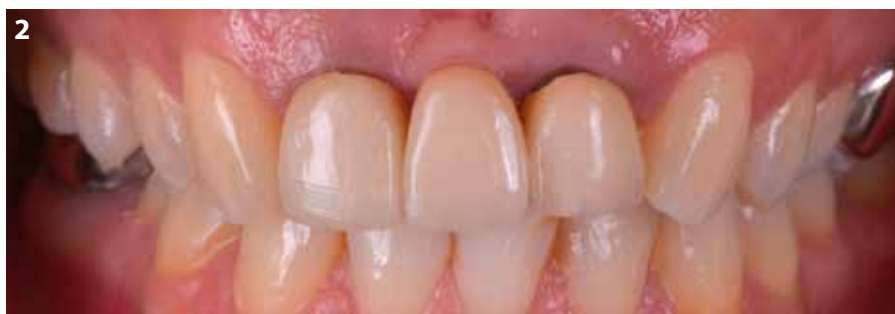

Fig. 2: preoperative intraoral view

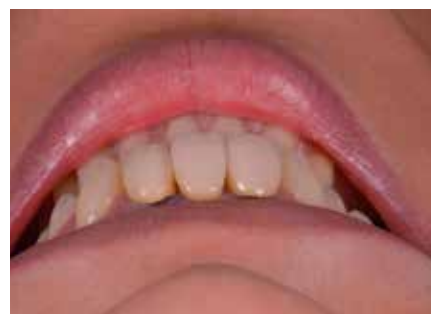

Fig. 3: preoperative view from the top

After clinical and radiographic assessment, the digital smile design was created. Two treatment options were evaluated, keeping in mind the minimum distance between two adjacent implant shoulders to preserve the crestal bone in between (Figs. 4-5):

- 1) Replacing the three-unit bridge by a four-unit bridge on two implants
 - With this option, it was not possible to obtain a good ratio of the crowns.
- 2) Replacing the three-unit bridge by two single restorations of the central incisors with reshaping of the canines and premolars.
 - This option gave the best crown ratios to achieve a harmonious result.

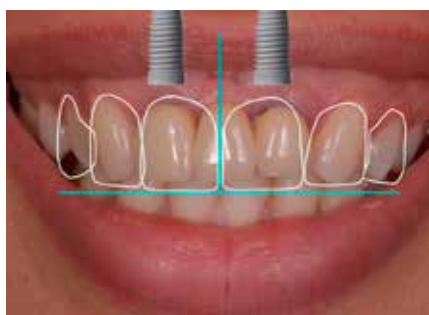
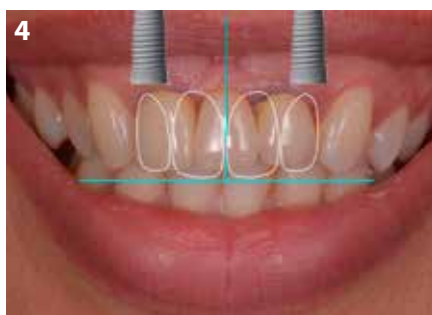
Fig. 4: Digital smile design (DSD) of two treatment options.

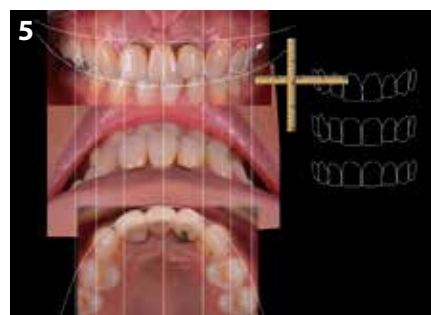

Fig. 5: Final DSD with frontal, top and occlusal view

The challenge of replacing adjacent incisors

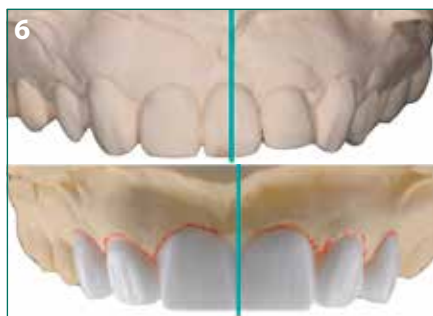

Fig. 6: Wax-up, frontal view

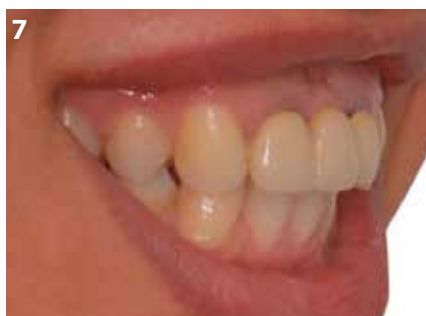
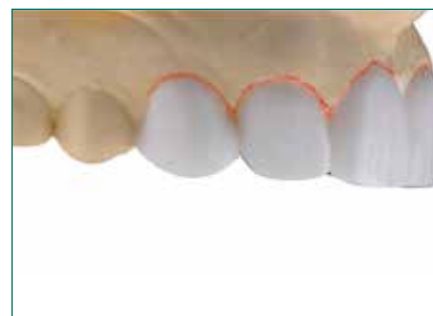
Fig. 7: Wax-up, side view



The second treatment option evaluated with the digital smile design served as a base for the wax-up (Figs. 6-8). The maxillary incisors were abraded and the shape of both canines and first premolars was altered to achieve a symmetrical design while respecting the tooth ratios. The design was evaluated together with the patient by means of an intraoral mock-up (Figs. 9-11).

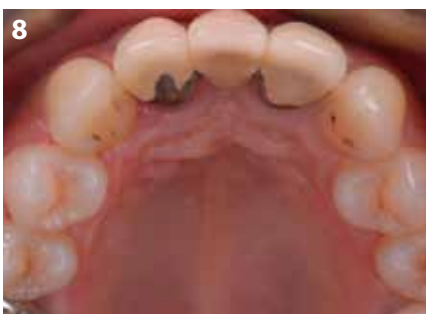

Fig. 8: Wax-up, occlusal view

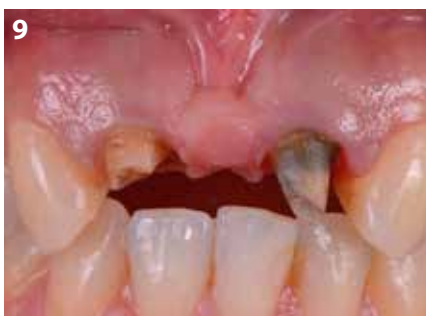
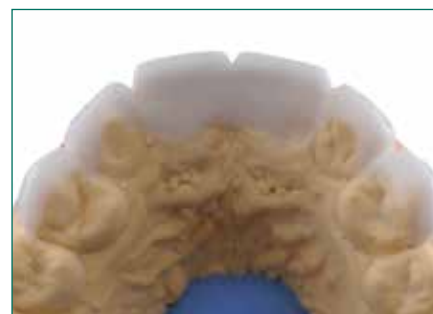
Fig. 9: Intraoral view after removal of the deprecated PFM restoration.

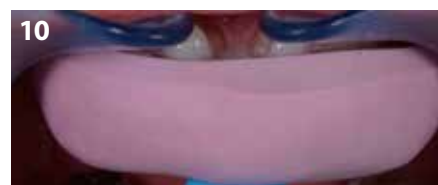
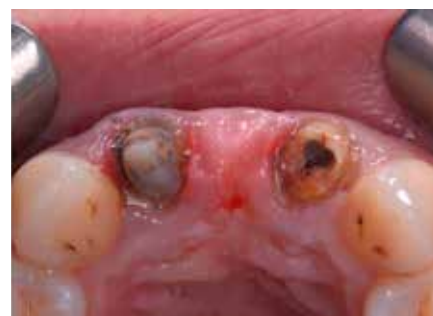
Fig. 10: Preparation of intraoral mock-up using a silicone key.

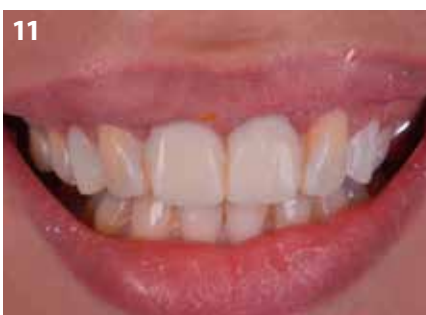

Fig. 11: Intraoral mock-up.



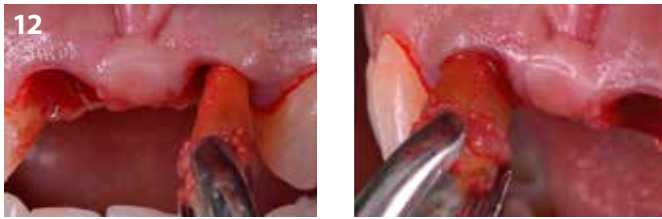


Fig. 12: Atraumatic removal of the radices.

The roots were extracted atraumatically under local anaesthesia (Fig 12). A crestal incision was made that was located slightly more towards palatal (Fig. 13)

Space was created up to the appropriate depth i.e. 12 mm with the pilot drill (Fig. 14). Proper alignment of the implant space was checked with regard to the adjacent and opposing teeth. The socket was then prepared by a sequence of drills with gradually increasing diameter, never exceeding 50 Ncm torque. An Standard Aadva implant, regular, 4 mm diameter, GC Tech, Breckerfeld, Germany was placed at a speed of 25 rpm in accordance with the manufacturer's instructions (Figs. 15-16) and the primary stability was checked.

A subepithelial connective tissue graft was augmented to achieve an inter-implant papilla (Fig. 17). Two healing screws were placed (Fig. 18).

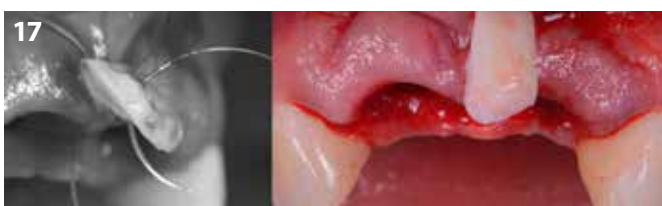

Fig. 17: Soft tissue Graft to increase the papilla between the central incisors

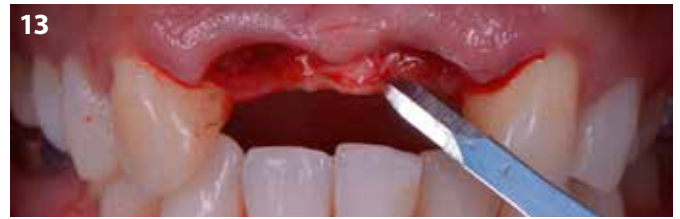

Fig. 13: Supracrestal incision, slightly towards the palatal side.

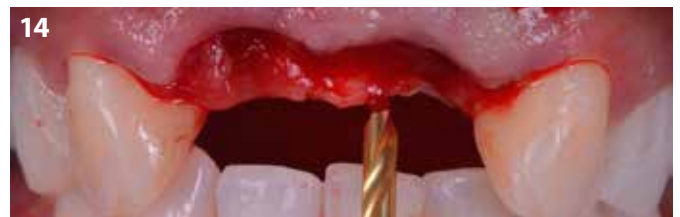

Fig. 14: Pilot drill

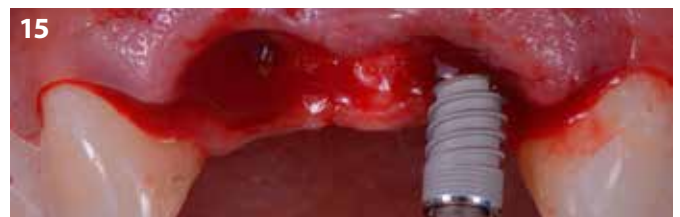

Fig. 15: Implant placement

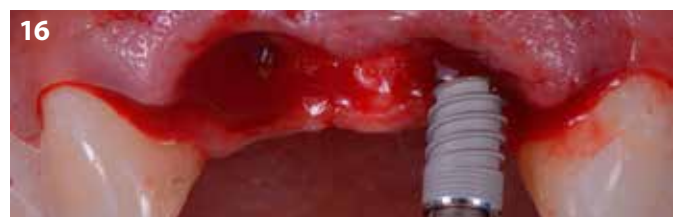

Fig. 16: Occlusal view on the implants after placement.

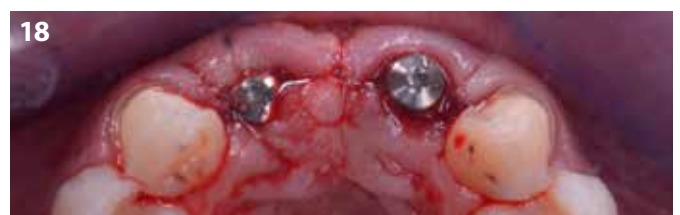

Fig. 18: After placement of the healing screws

The challenge of replacing adjacent incisors

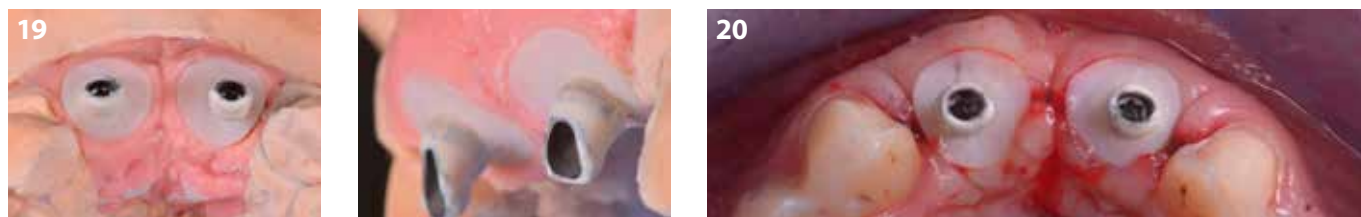


Fig. 19-20: Creation of the temporary abutments with a natural emergence profile to support the gingiva

Temporary customised abutments and acrylic provisionals were prepared in the lab (Figs. 19-20). Care was taken to prepare a subgingival emergency profile that gave a smooth transition from the implant platform to a natural tooth shape at the gingival level, supporting and shaping the gingiva around the implant (Figs. 21-23).

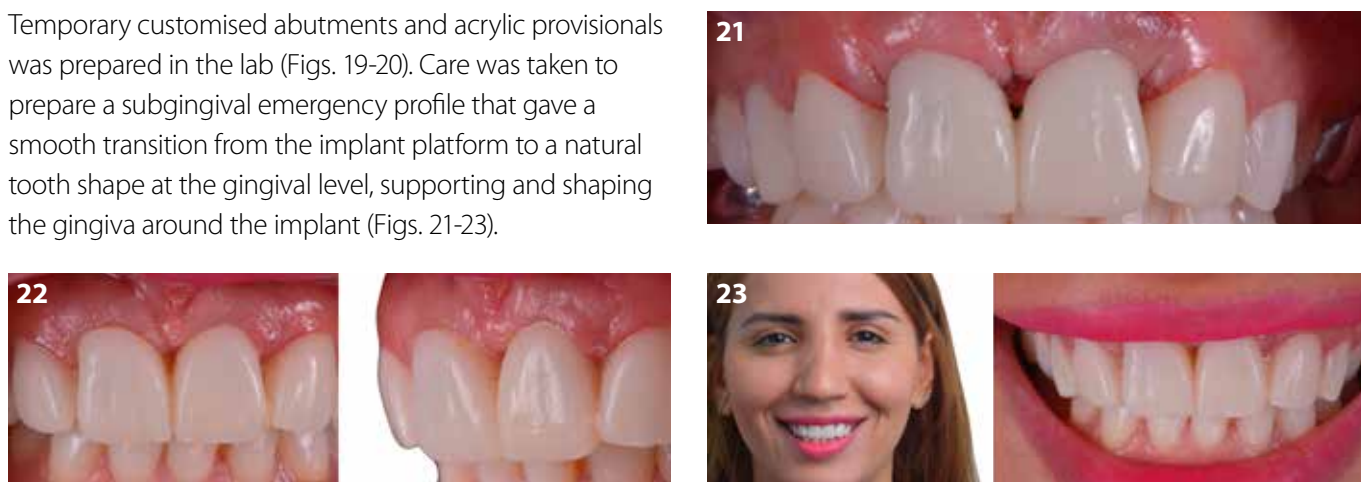


Fig. 21-23: Temporary restorations screwed onto the implants

After a period of 6 months, soft tissues were healed and adapting to the provisional crowns (Figs. 24-26).

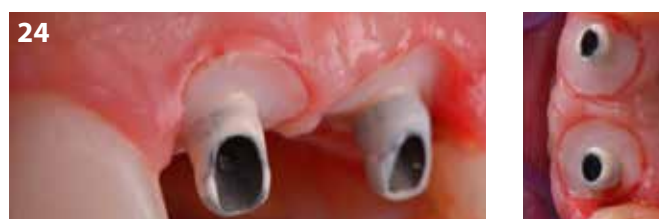

Fig. 24: View on the temporary abutment after a healing period of 6 months.

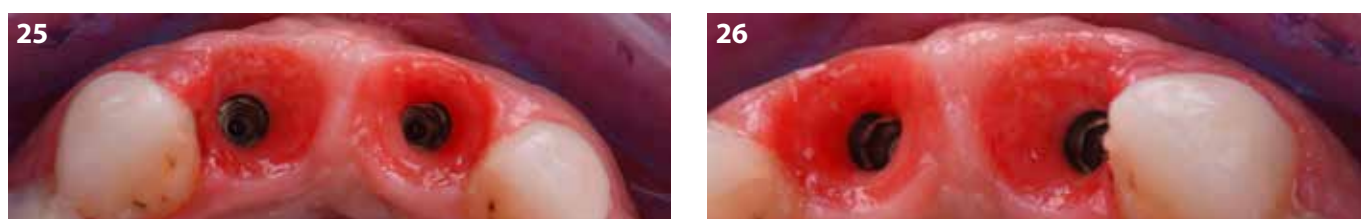

Fig. 25-26: After removal of the temporary abutments. The gingival tissue is shaped.

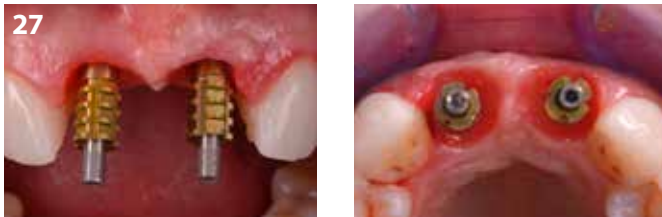

Fig. 27: Impression on implant level (pick-up technique)

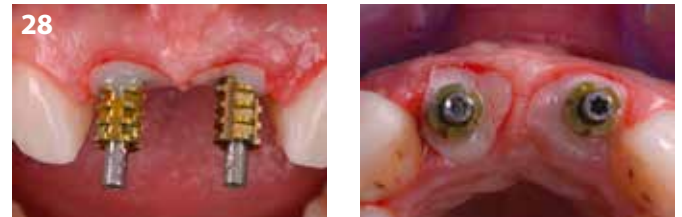

Fig. 28: customisation of impression copings to copy the emergency profile.

An impression post was individualised with acrylic resin to copy the emergency profile shaped in the period of temporisation and the final impression was made with a pick-up technique (Figs. 27-28).



Fig. 29: GC Hybrid abutments (Zr suprastructure on Ti base)

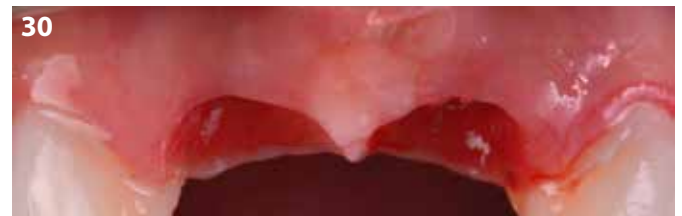

Fig. 30: Frontal view before inserting the custom abutments

Two customised CAD-CAM abutments (GC Tech Milling Centre, Leuven Belgium) from a zirconia suprastructure on a titanium base (GC Hybrid Abutment, GC Tech) were prepared and screwed onto the implants with 20 Ncm torque (Figs. 29-32). The ceramic crowns were then cemented onto the abutments (Figs. 33-34). The final result showed a symmetric smile with preservation of the papillae between both implants and between the implants and adjacent teeth.

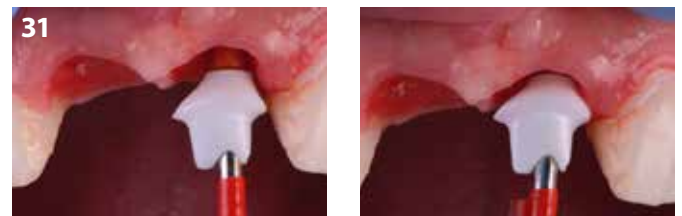

Fig. 31: The custom Zr abutments were screwed on the implant

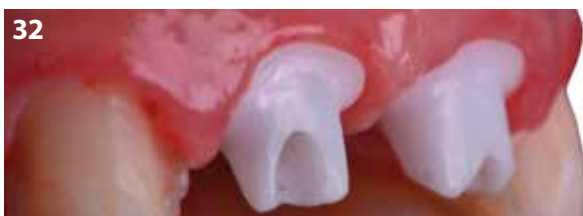

Fig. 32: The custom Zr abutments after proper seating.

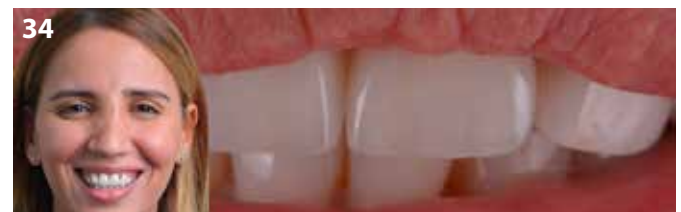
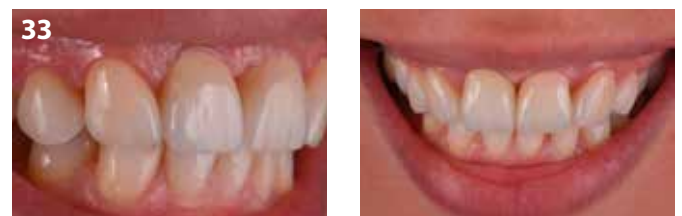
Fig. 33-34: Final result

Conclusion

Implant placement is restoratively driven, but the surgical step is key in determining the aesthetic potential. Understanding the biological concepts and maintaining a strict surgical and prosthetic protocol are therefore crucial.

References

1. Tarnow D, Elian N, Fletcher P, Froum S, Magner A, Cho SC, Salama M, Salama H, Garber DA. Vertical distance from the crest of bone to the height of the interproximal papilla between adjacent implants. *J Periodontol*. 2003 Dec;74(12):1785-8.
2. Chu SJ, Tarnow DP, Tan JH, Stappert CF. Papilla proportions in the maxillary anterior dentition. *Int J Periodontics Restorative Dent*. 2009 Aug;29(4):385-93.



Dr. Matteo BASSO, DDS, PhD, MSc
Dentist, PhD in oral implantology and
implant-prosthetic rehabilitation, specialist
in oral surgery. Adjunct Professor of the
University of Milan for the courses of
Ergonomics, Business Economics and
Periodontology.
He is actually the head of the Minimally
Invasive, Aesthetic and Digital Oral
Rehabilitation Center (CROMED) at the
IRCCS Galeazzi Orthopedic Institute in Milan.
Member of IADR, ORCA and TRAP-Active
member. Founding member of the
Minimum Intervention Treatment Plan
Advisory Board.



Dr. Arturo DIAN, DDS
Dentist and university tutor of the dental
clinic of the University of Milan at the IRCCS
Galeazzi Orthopedic Institute of Milan.
He focuses his activity on digital, prosthetic
and implant procedures.

Implant shape and immediate loading: the Aadva solutions

By Dr. Matteo Basso and Dr. Arturo Dian,
Italy

Nowadays, immediate load rehabilitations are a very widespread practice in modern dentistry. Faced with the clinical need to proceed with the elimination of dental elements that are no longer maintainable, it is now possible to efficiently replace the teeth within a few hours of surgery, with a reduction in the discomfort and social difficulties of patients.

However, in order to prevent adverse events and complications in the early and later stage - cfr. the non-integration of titanium dental implants - immediate loading rehabilitation requires a very careful planning at the patient as well as at the implant and prosthetic materials level.



Implant shape and immediate loading: the Aadva solutions.

It is evident that the central issue to be observed during an immediate loading procedure is the creation of a good primary stability of the dental implant¹⁻³. There is sufficient scientific evidence available to proof that the degree of primary stability achieved during immediate loading protocols depends on several factors: bone density and quality, surface design

and characteristics, surgical technique and implant shape. Conical implants seem by far the ones that can most easily guarantee the achievement of primary stability²⁻³: on average they require a higher insertion torque than cylindrical implants, they allow to perform bone thickening and compaction on the osteotomy walls during their insertion and their shape

allows them to be equipped with even quite large turns without considerably increasing the overall diameter of the implant and the need for bone volumes. According to some authors, the advantage given by the choice of a conical implant for primary stability is even higher than that given by the choice of the surgical technique³.

CLINICAL CASE

A 78-year-old female patient requested an urgent treatment for the instability of a metal-ceramic prosthesis of the upper arch she received about 20 years earlier (Figure 1). Clinical and radiographic examination showed (Figure 2) that the abutments of many natural elements were fractured, carious and periodontal lesions were detected not allowing the dental elements of the upper arch to be retained. In addition, the panoramic X-ray showed 2 visible dental implants: a monobloc blade implant in position 24, which was mobile and surrounded by fibrous

tissue, and a cylindrical implant with wide spires, with an internally cemented abutment, stable but not ideally positioned for an immediate loading procedure.

A CT scan of the upper dental arch was performed revealing a sufficient amount of bone for the All-on-4 rehabilitation technique with the placement of dental implants in site 15, 12, 22. In site 25 the placement of a fourth implant was planned. Nevertheless, a guided bone regeneration (GBR) had to be planned because of a fibrous lesion due to the

loss of the integration of the previous blade implant. On top, the preservation of the old implant in position 23, to still allow an immediate loading procedure without loading the implant 25, was not possible in this case as a good primary stability of this new implant could not be guaranteed. Before the intervention, alginate impressions were taken to create a surgical guide to also be used as a support to register the vertical height. In order to reduce the risk of passage of periodontal pathogenic bacteria in the blood, the patient was then

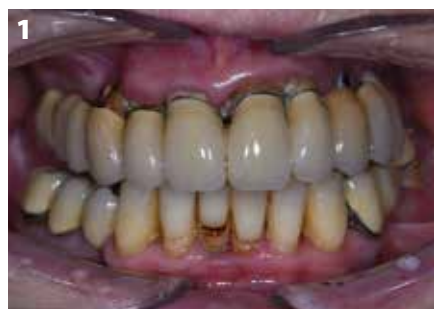

Fig. 1: Initial situation. The bridge in the upper arch is mobile and can no longer be recovered due to the breaking of numerous abutments.

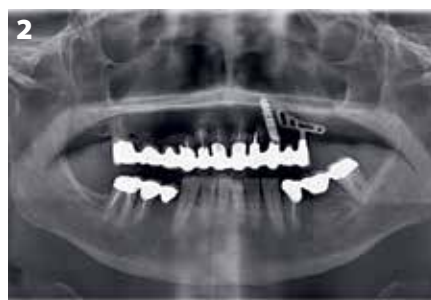

Fig. 2: Initial panoramic radiography. The presence of 2 old-type implants is noted in the second quadrant, with a peri-implant lesion extended on the 25-blade implant.

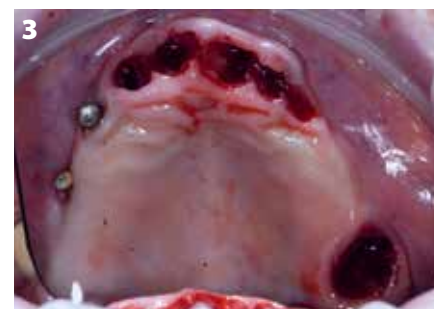

Fig. 3: Extraction of the natural dental elements in the upper arch.

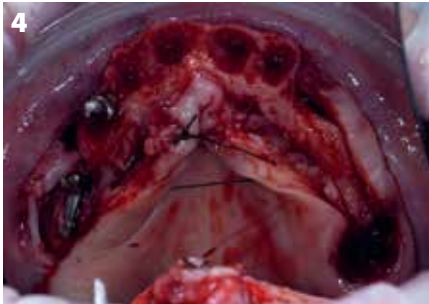

Fig. 4: Opening of a flap from 16 to 26 and removal of the odontogenic cystic lesions with contextual osteoplasty.

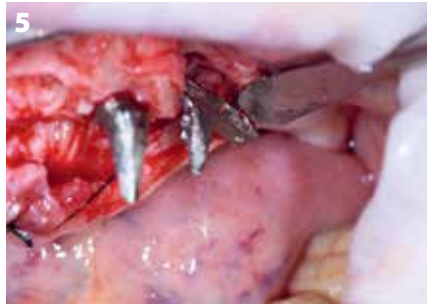

Fig. 5: Elimination of the blade implant in position 25, which was mobile and lacking in osseointegration.

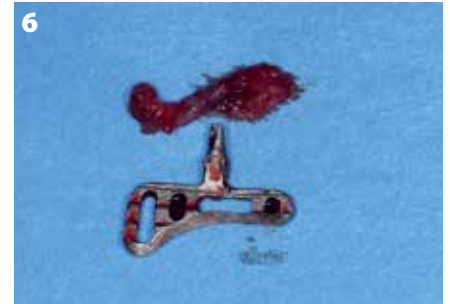

Fig. 6: Appearance of the blade implant and attached peri-implant cyst.

prescribed with antibiotic and prophylactic antiseptic therapy with amoxicillin + clavulanic acid tablets 1g every 12 hours for 6 days, starting the night before (Augmentin, GSK, Great Britain) and with chlorhexidine 0.20% with anti-pigmentation system and Sodium-DNA rinsing every 12 hours for 14 days, starting 3 days before (Curasept ADS-DNA, Curasept SpA, Italy). On the day of surgery, under conscious sedation, upper teeth were extracted (Figure 3) and a full-thickness flap from 16 to 26 was opened (Figure 4). In region 25, the mobility of the blade

implant was immediately evident and could easily be removed by levering distal to it (Figure 5), eliminating the massive cystic lesion that extended to the adjacent mesial implant (Figures 6 and 7). The implants selected for the patient's rehabilitation were 4 Aadva Tapered implants (GC TECH, Germany) with a diameter of 4.0 mm and a length of 14 mm, with a conometric connection. The 2 anterior implants were then inserted (Figure 8) with subsequent insertion of the abutments (Figure 9) and the inclined implant in position 15 (Figure 10) with the SR abutment

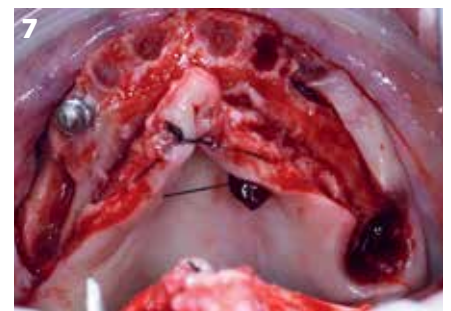

Fig. 7: Appearance of the upper arch after osteoplasty, removal of cysts and curettage of the alveoli.

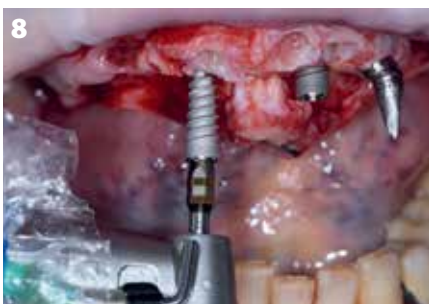

Fig. 8: Insertion of the Aadva tapered implants in orthogonal position 12 and 22.

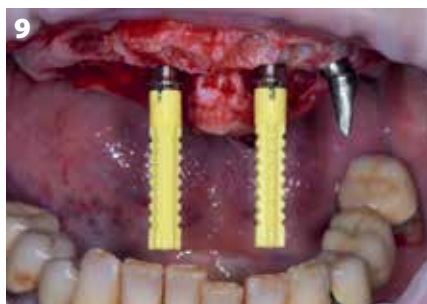

Fig. 9: Insertion of the straight Aadva SR abutments on implants 12 and 22.

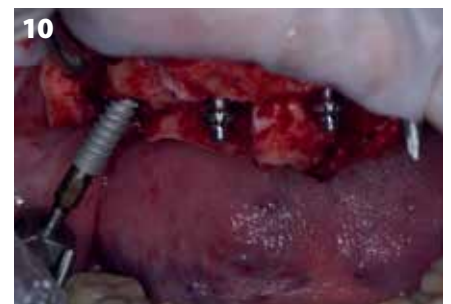

Fig. 10: Insertion of the tilted implant in place 15. The bone volume appears sufficient.

Implant shape and immediate loading: the Aadva solutions.

angled at 30 ° (Figure 11). Subsequently, the last implant was inserted in site 25. Surprisingly, despite the large cystic lesion after the removal of the blade, it was possible to insert the implant

with a torque of 50 Newton (Figures 12 and 13). Decision was taken not to keep the old implant on site 23 and to remove it during the procedure. A guided bone regeneration of the

area of 25 with deproteinized bovine bone (Bio Oss, Geistlich) and resorbable collagen membrane (BioGide, Geistlich) was therefore performed (Figures 14, 15, 16).

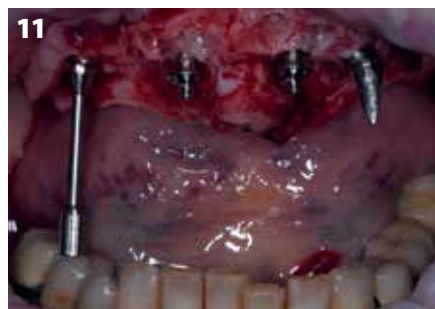

Fig. 11: Application and verification of the orientation of the 30 ° SR inclined abutment.

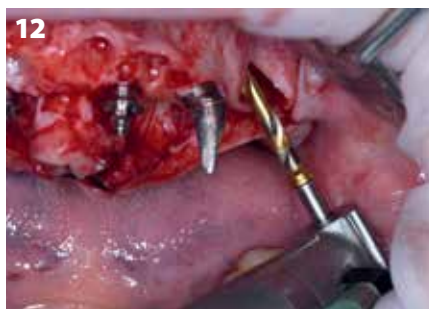


Fig. 12: Preparation of the implant site of 25. The site coincides with the osteolytic area linked to the presence of the previous blade implant and the bone volume appears reduced.



Fig. 13: Despite the reduced bone volume, the conical implant allowed an insertion torque of 50 N.

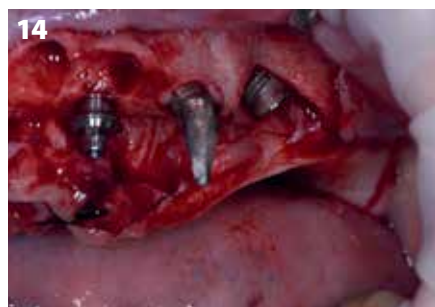

Fig. 14: The implant on 25 position is not fully inserted as planned in the preoperative planning and guided bone regeneration was required in the crest area.

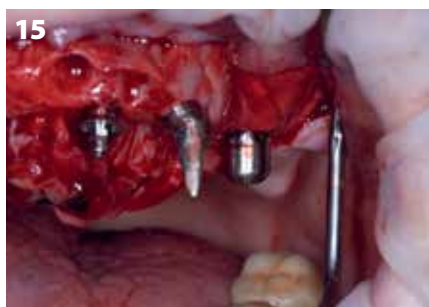


Fig. 15: Application of the 30° SR abutment, the healing screw and the bone graft covered by a reabsorbable bovine collagen membrane.

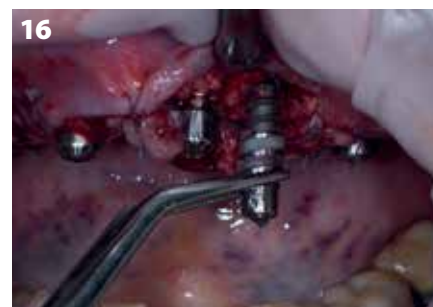

Fig. 16: Elimination of the implant in position 23, which was useless for temporary rehabilitation due to the high primary stability of the new implant in site 25.

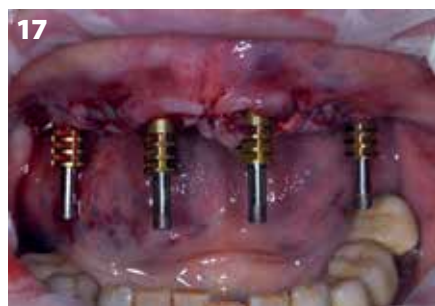

Fig. 17: Positioning of the coping transfers for open tray technique for taking the silicone impression.

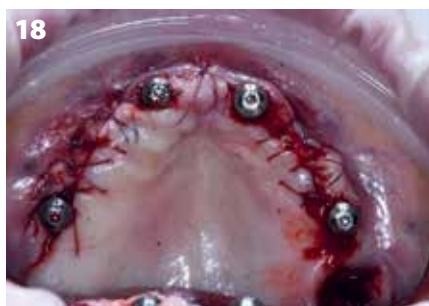

Fig. 18: Application of the special healing screws on the SR abutments for the discharge of the patient pending the fabrication of the temporary prosthesis.

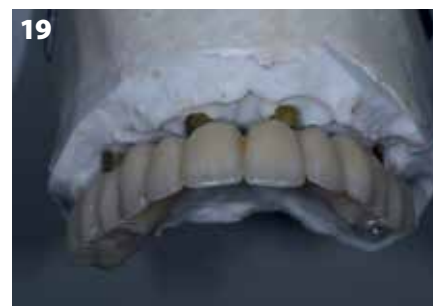

Fig. 19: Provisional prosthesis, front view. In agreement with the patient, no pink gingival compensations were inserted.

Resorbable suture (Vycril 5/0, Ethicon, US) was placed and a polyvinylsiloxane impression was taken (Figure 17).

After application of the protective cap on the SR Abutments (Figure 18), the patient was discharged.

The following day, as requested by the patient, a reinforced resin prosthesis without a pink resin part (Figures 19 and 20) with a correct prosthetic emergency for conditioning the tissues in the healing phase (Figures 21, 22 and 23) was delivered.

The screws were tightened to 15 Newton and the access holes were temporarily sealed with impression silicone to facilitate removal of the

prosthesis, if required during follow-up. The final radiograph showed a correct fit of the prosthesis on the SR prosthetic abutments (Figure 24).

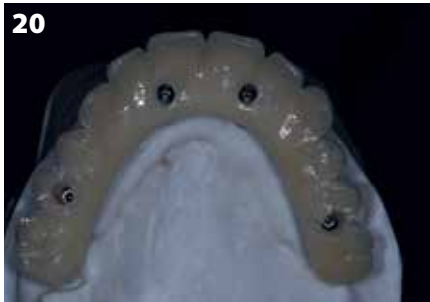

Fig. 20: Provisional prosthesis, occlusal view. Note the correct emergence of the path of the connecting screws, which also allowed the insertion of the first molars for the reduced distal cantilever.

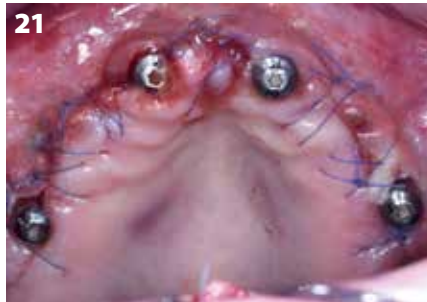

Fig. 21: Appearance of the mucous membranes 24 hours after surgery. There is edema and swelling, which may require the execution of anesthesia for the placement of the temporary prosthesis.

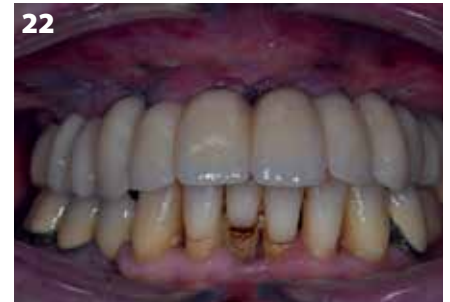

Fig. 22: View of the temporary prosthesis in position: note the absence of ischemia or excessive compression of the tissues traumatized by surgery.

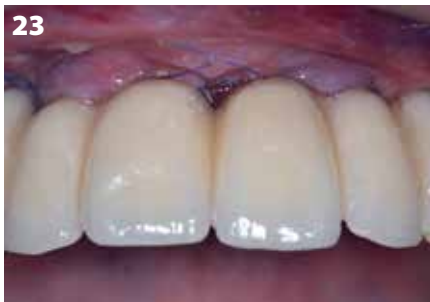

Fig. 23: Soft tissue conditioning is important especially at the level of the aesthetic area.

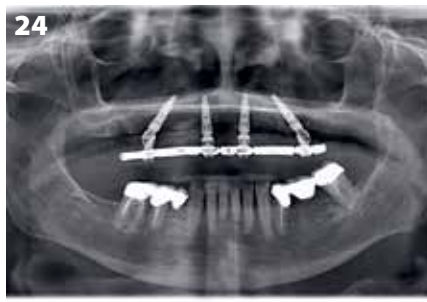

Fig. 24: Final x-ray after placement of the provisional upper prosthesis showing the correct coupling of the prosthetic connections and the correct and symmetrical positioning of the implants.

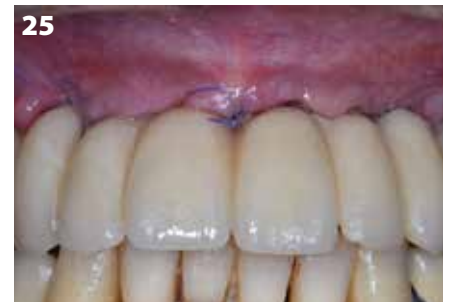

Fig. 25: Aspect of the soft tissues, 7 days after immediate loading.

Final remarks

The use of AADVA tapered implants with internal conometric connection allowed a correct positioning according to the All-on-4 immediate loading rehabilitation technique. The particular conical shape of the implants and the aggressive wide pitch thread allowed a high primary stability even at implant site 25, where the volume and the quality of the bone were not ideal compared to other implant sites. This means that the particular shape and design of AADVA tapered implants,

when positioned in an area without a satisfactory bone volume, can facilitate immediate loading, eventually contextual to a regenerative procedure, since it guarantees optimal primary stability. As a final consideration, the particular shape of the conometric connection with platform switching⁴ can also be particularly advantageous in the early healing phases of an immediate loading for both soft and hard tissues.

Bibliography

1. Valente ML, de Castro DT, Shimano AC, Lepri CP, dos Reis AC. Analysis of the influence of implant shape on primary stability using the correlation of multiple methods. *Clin Oral Investig*. 2015 Nov;19(8):1861-6.
2. Karl M, Grobecker-Karl T. Effect of bone quality, implant design, and surgical technique on primary implant stability. *Quintessence Int*. 2018 Jan 22;189-198.
3. Elias CN, Rocha FA, Nascimento AL, Coelho PG. Influence of implant shape, surface morphology, surgical technique and bone quality on the primary stability of dental implants. *J Mech Behav Biomed Mater*. 2012 Dec;16:169-80.
4. Macedo JP, Pereira J, Vahey BR, Henriques B, Benfatti CAM, Magini RS, López-López J, Souza JCM. Morse taper dental implants and platform switching: The new paradigm in oral implantology. *Eur J Dent*. 2016 Jan-Mar;10(1):148-154.



Dr. Alex Dagba graduated from Paris V University Descartes (France) in 2009. After obtaining his DDS, he practiced in Paris for four years and completed several University Certificates (C.E.S.) in Periodontology, Biomaterials and Fixed Prosthodontics. To improve his skills in Implant Dentistry he followed the New York University (NYU) Advanced Education in Implant Dentistry program for the years 2013-2015. The following year he became ICOI diplomate. His activities in Paris are now focused on implant dentistry and aesthetics. Since 2016, he is Chief Editor of the French Quintessence-International Implant Journal, "Titane".



Dr. Romy Makhoul graduated from Paris V University Descartes in 2012. She was a resident in Oral Surgery from 2012 to 2016 at Clermont Ferrand Faculty and is working at the Faculty of oral Surgery of University Lyon I since 2016. She is a member of the SFCO (French Society of Oral Surgery) and has a private practice in Paris, focusing on oral surgery, dermatology and implantology.



Dr. Julien Mourlaas graduated from Paris V University Descartes in 2011. After a few years as a general dentist, he enrolled the International Implant program at NYU. Back in France, he limited his practice in the field of Periodontology and Implant Dentistry with a special tropism for perioplastic surgery. Dr. Julien Mourlaas is also involved in managing publications (co-Chief Editor at "Titane") and microsurgical training (Paroplastic).

Single tooth replacement in the aesthetic zone: contribution of the socket preservation technique to a durable end result

By Dr. Alex Dagba, Dr. Romy Makhoul and Dr. Julien Mourlaas, France

Aesthetic restoration of anterior teeth with implant-supported restorations is one of the most difficult procedures to execute, in particular when deficiencies exist in the bone and soft tissues. Nowadays, implant survival rates are rather high, with reported rates over 95% after ten years.¹

Hence, the focus in dental implantology has shifted from survival of the implant to soft tissue management, alveolar ridge preservation and obtaining an aesthetic end result. Complete reconstruction of tooth and gingival related aesthetics remains the primary objective and in some instances can be very difficult to achieve.

Single tooth replacement in the aesthetic zone: contribution of the socket preservation technique to a durable end result.

Case report

A 42-year-old female patient was referred to our clinic to have her tooth #21 replaced, which was painful and had slightly migrated coronally. She had a history of trauma from when she was a teenager. The patient had an average smile line with extrusion of tooth #21 (Fig. 1). The gingival biotype was reasonably thick associated with a pronounced scallop. A fistula with pus was related to the apex of the tooth. A CBCT was made to assess the bone thickness and to determine the alveolar shape and sagittal root position of the tooth (Figs. 2-3).

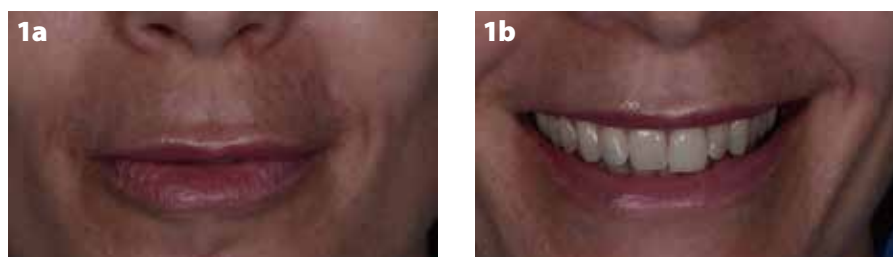

Fig. 1: Preoperative extraoral view: lips in rest (a); smile (b).

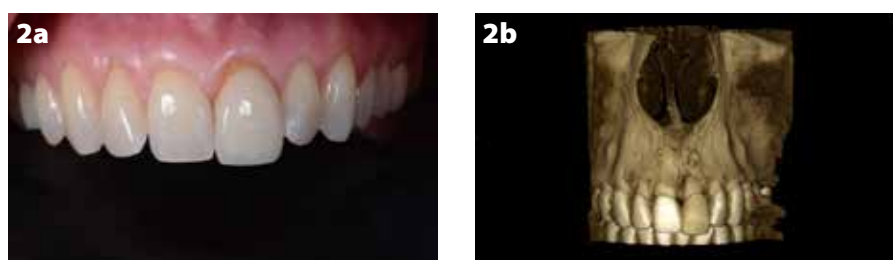

Fig. 2: Preoperative intraoral view (a); 3D rendering from CBCT of the bony structures (b). The periapical fenestration is clearly visible.

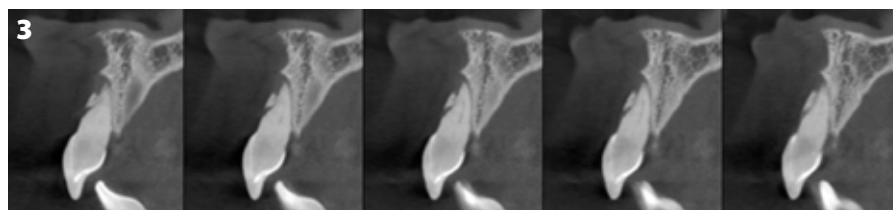


Fig. 3: CBCT sagittal view of tooth 21. Notice the buccal dehiscence.

The patient was primarily referred to an endodontist to assess the predictability of an endodontic treatment, but the prognosis of such an approach wasn't favourable. This was due to an important bone dehiscence buccally associated with a fenestration localised at the root apex. The intraocclusal space was narrow due to the deep overbite. Hence, it was decided to replace tooth #21 with an implant-supported crown, leaving the adjacent teeth in their current state.

Ideally, 2 mm of bone at the buccal side of the implant is considered

necessary to ensure proper soft tissue support and to avoid gingival recession after treatment.

In this case, the soft tissues were well positioned: the tooth was extruded but no recession was present. The buccal bone was partially absent, corresponding to a socket type II according to Elian et al.²

Clinical protocol

The most difficult aspect in such a case is to maintain the soft tissue architecture and to keep the adjacent papillae. Because of the bone dehiscence, a

socket preservation approach was chosen.

Surgical phase

Tooth #21 was atraumatically extracted using a periosteal elevator, following the periodontal ligament (Fig. 4) and stored

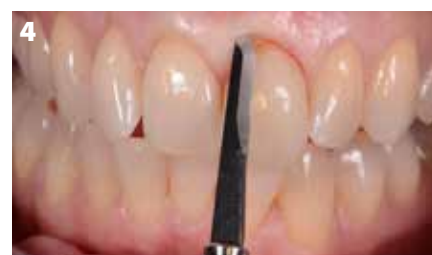

Fig. 4: Atraumatic extraction of tooth 21 using a blade in the sulcus.

Single tooth replacement in the aesthetic zone: contribution of the socket preservation technique to a durable end result.

in an isotone saline solution to be used as a provisional restoration in the second treatment phase. The goal was to preserve the surrounding tissue as much as possible and to limit any further bone resorption.

The socket was filled with allograft particles (Phenix, TBF; Fig. 5), gently packed and covered with an L-PRF membrane to protect the socket graft (Fig. 6). The role of the L-PRF membrane is that case is essentially mechanical, to avoid any eventual dispersion of the graft material in the early stage of the healing until a stable blood clot occurs. No tissue graft harvest was needed.

During the whole socket healing period for 4 months³, a composite provisional tooth was bonded to the adjacent teeth. Some composite was placed palatally in the coronal part to avoid discomfort during occlusion. The provisional was placed slightly buccally to decrease the load in occlusion (Fig. 7).

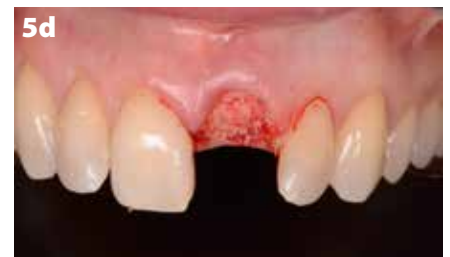
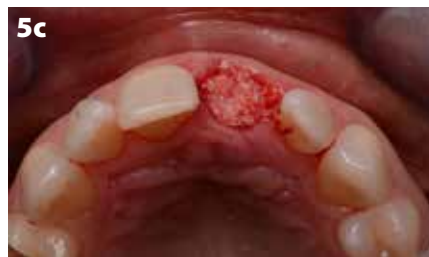
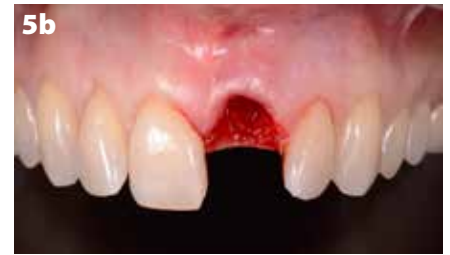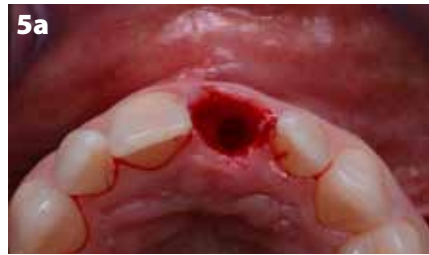Fig. 5: Occlusal and frontal views following the extraction (**a&b**), and after filling with allograft particles (Phenix, TBF) (**b&d**).

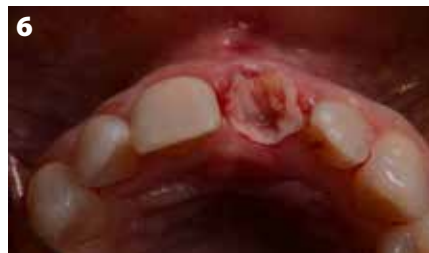

Fig. 6: Socket coverage with L-PRF membrane.

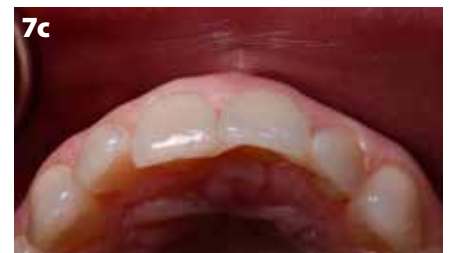
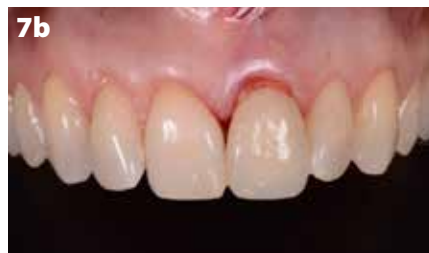
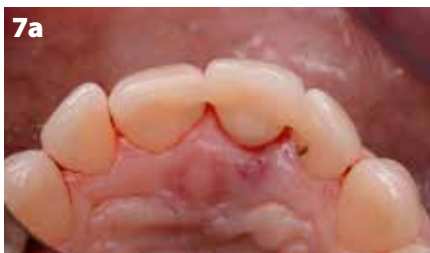Fig. 7: After the socket preservation procedure, a composite-resin provisional tooth was bonded to the adjacent teeth with a flowable composite occlusal view (**a**); buccal view (**b**); vestibulo-occlusal view (**c**).

The ovate shaped pontic of this provisional extended into the extraction socket in order to shape the soft tissue and to support the adjacent papillae (Fig. 8).⁴ Without support, there is more risk of papilla collapse.

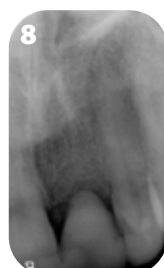

Fig. 8: X-ray of the extracted site, 4 months post-op. Note the composite pontic extending into the extraction socket.

Single tooth replacement in the aesthetic zone: contribution of the socket preservation technique to a durable end result.

Four months later, the site had healed properly (Fig. 9): the soft tissue was well positioned and the papilla was preserved. The bone volume was well maintained; there was no buccal concavity and a proper ridge contour

(buccal-palatal) could be seen. At this point, the main objective was reached: good post-surgical healing could be observed. The focus from then on was to preserve the healed soft tissue architecture: scar tissue development

and cutting of the blood supply had to be avoided: therefore, a narrow flap raising was used, combined with guided surgery with a pilot drill guide (Fig. 10).

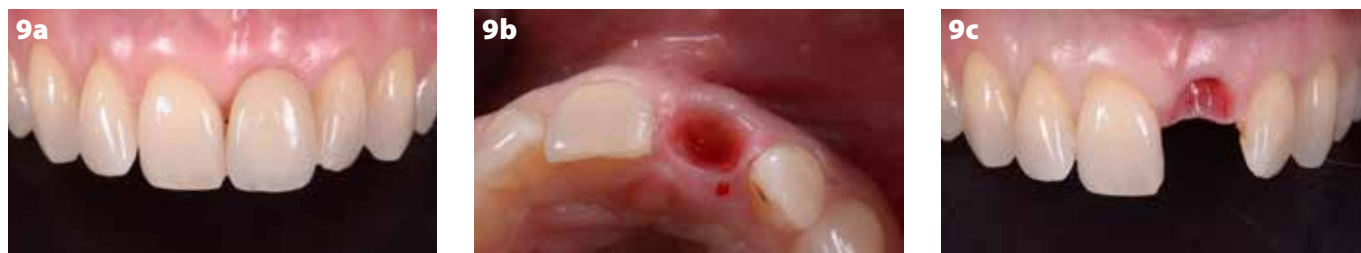

Fig. 9: Clinical views of the extracted site after a healing period of four months with (a) and without the provisional tooth (b, c).

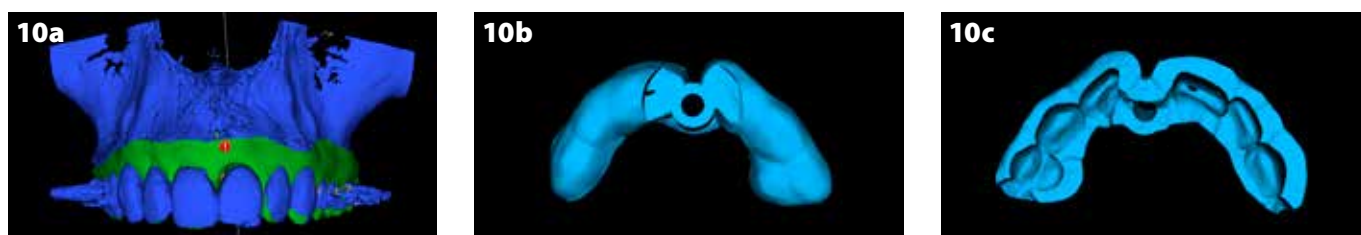


Fig. 10: A pilot drill guide was planned and designed based on STL files.

An implant (Aadva Regular, GC Tech) with conical internal connection and platform switch was placed (Figs. 11-12).

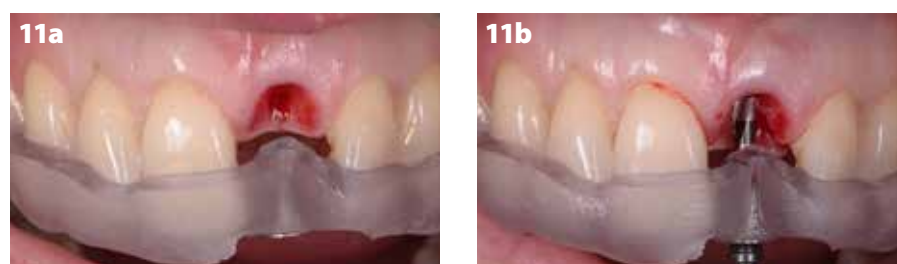

Fig. 11: Surgical guide (a) optimising the drill position of the pilot drill (b).

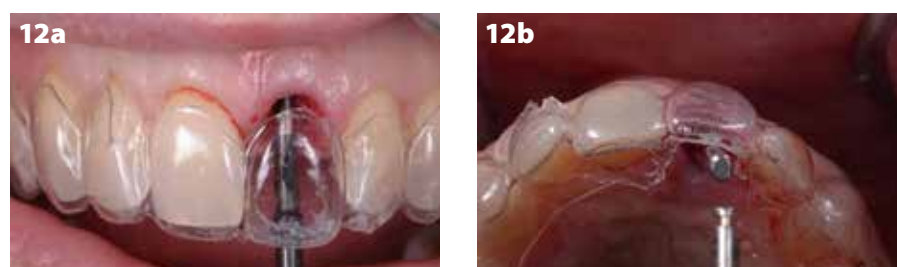

Fig. 12: A second guide is based on diagnostic wax-up. Tooth morphology and emergence profile were reproduced and served as a reference for the implant positioning (a & b).

Single tooth replacement in the aesthetic zone: contribution of the socket preservation technique to a durable end result.

After placement, the provisional restoration was rebonded to the adjacent teeth (Fig. 13a). Four months later, the implant was osseointegrated. Once again, good soft tissue integration was obtained (Fig. 13b). From that step, the prosthetic phase could begin.

Prosthetic phase

A customised screw-retained provisional was prepared using a shell from the buccal part of the extracted tooth (Fig 14a).⁵

The shell was placed over a titanium provisional abutment (Provi Abutment, Aadva) and fixed with composite (Fig. 14b). Then, the transgingival part

One of the customised provisional goals is to enable the creation of an exact replica of the emergence profile on a custom impression coping. To prepare the customised impression coping, an implant analogue was fixed inside a Dappen dish and the customised temporary restoration was screwed on top (Fig. 15). The Dappen dish was filled with impression silicone to copy the trans-gingival profile of the temporary restoration (Fig. 16). The impression coping was then screwed onto the implant analogue, so the emergence profile could be duplicated with flowable composite (Fig. 17).

The instant a temporary restoration is unscrewed, the tissue shape begins to collapse. Hence, a customised impression coping was used to provide a model for transferring the position of the implant, the hex orientation of the connection as well as the soft tissue contour.

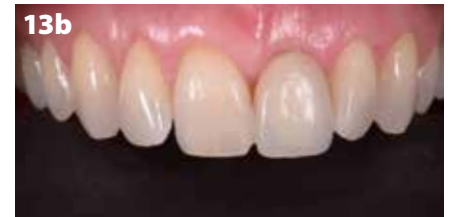
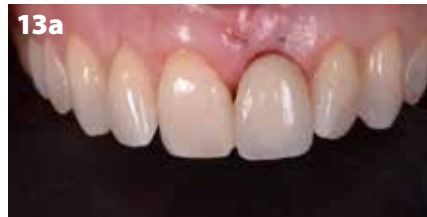
Fig. 13: Clinical frontal views immediately (a) and four months (b) after implant placement.

of the temporary crown was shaped to create a suitable emergence profile.⁵ This step is critical for the optimization of the pink aesthetics during tissue maturation.

The occlusion was adjusted to attain even centric occlusal contacts and subsequently reduce anterior guidance of the implant.

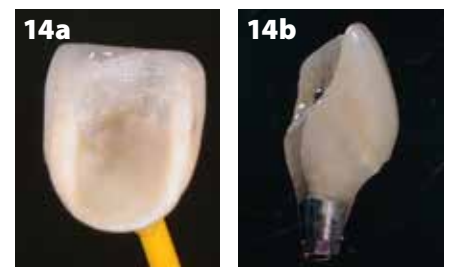


Fig. 14: Utilization of the extracted tooth buccal shell (a) on a provisional abutment to shape a screw-retained implant supported provisional (b).




Fig. 15: The implant analogue was fixed inside a Dappen dish (a) and the customised temporary restoration was screwed on top (b).





Fig. 16: The Dappen dish was filled with impression silicone to copy the emergence profile of the customised temporary restoration.

Fig. 17: The impression coping was then screwed on top and the emergence profile was duplicated with acrylic resin.

Single tooth replacement in the aesthetic zone: contribution of the socket preservation technique to a durable end result.

The custom impression coping was therefore positioned onto the implant inside the mouth (Fig. 18), seated with a direct pick-up coping screw and an

impression was taken with the pick-up technique (open tray; Fig. 19). The temporary crown was then immediately repositioned to avoid further

shrinkage of the soft tissues. With this impression technique, the technician can make an accurate soft tissue model.

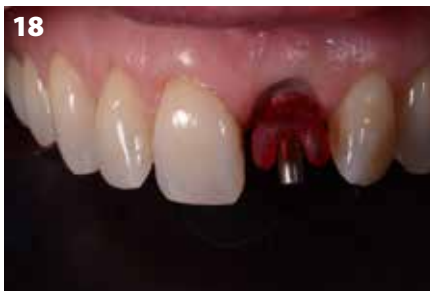

Fig. 18: The impression coping was screwed onto the implant.

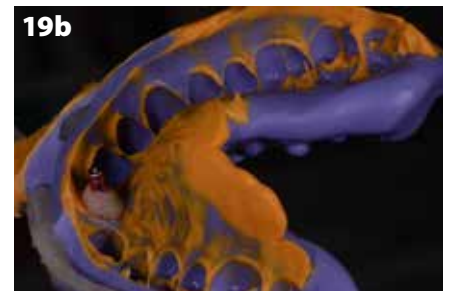
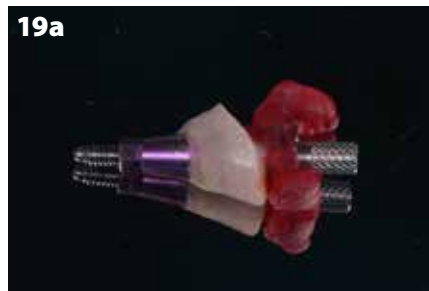

Fig. 19: (a) customised impression coping and (b) final impression with the customised impression coping.

A screw-retained lithium disilicate crown was finally placed (Fig. 20) and torqued following the recommendation of the manufacturer, 20 Ncm.

At the follow-up after 5 years, an aesthetic result was seen with adequate position of the crown and surrounding implants (Fig. 21). The radiograph showed an adequate bone level and tight implant-abutment connection (Fig. 22).

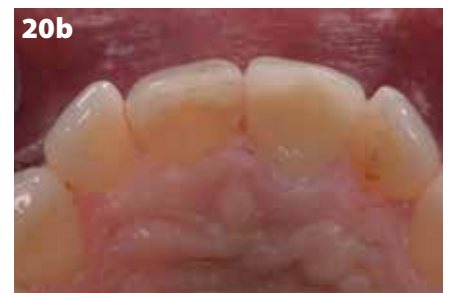
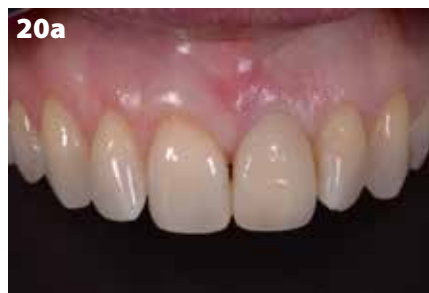
Fig. 20: Clinical view of the final crown (a) extraoral view and (b) occlusal view.

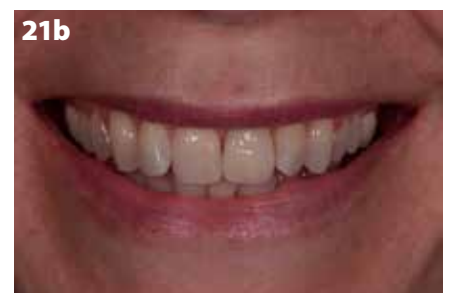
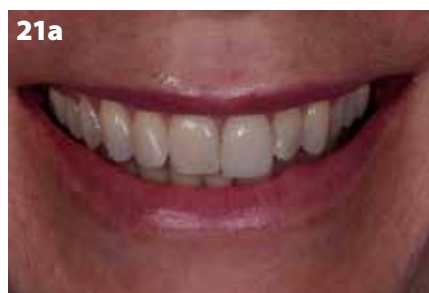
Fig. 21: Smile (a) before and (b) after treatment.

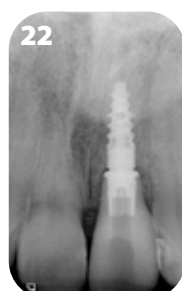

Fig. 22: Follow up after 5 years: X-ray of the implant with the crown.

Discussion

In this case, the amount of buccal bone adjacent to tooth #21 was limited. An immediate implant placement could have been considered in such a case, although with less predictable outcomes. It would have posed a risk of soft tissue recession and could potentially lead to a suboptimal result: hence, a socket preservation technique was chosen.

A soft tissue graft was dispensable since the soft tissue had a proper thickness, with sufficient amount of keratinised tissue and the contour was preserved.

No guided bone regeneration was expected from the L-PRF membrane, but it was used to stabilise the graft material. Even though it might strictly not be necessary, it was one more security that had been built in.


A bonded bridge could also have been an alternative in this case. However, because of the patient's age, the narrow intraocclusal space and to preserve the adjacent teeth, implant treatment was preferred. Indeed the overbite was low and the overbite was more than 3mm. After implant placement, a screwed provisional could have directly been placed, since a high insertion torque was reached (>40 Ncm). However,

since the bonded provisional was comfortable for the patient and it was fast and easy to replace, the customised provisional was prepared in a next session.

Conclusion

Sometimes it is forgotten that socket preservation is a still a nice weapon in our arsenal. For challenging cases as this one, with a bone deficiency in the aesthetic zone, it is extremely important to follow the basic rules, respecting biological concepts and natural healing to obtain a stable result in a predictable way.

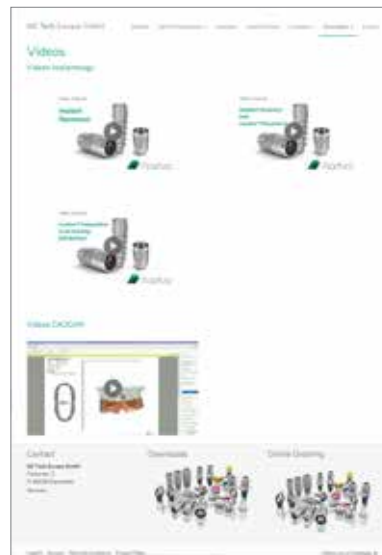Supportive Tools available for download



Brochures



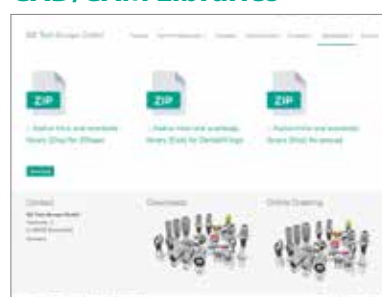Video's



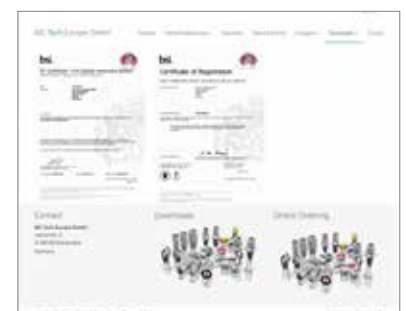Publications



CAD/CAM Libraries



Certificates





For more information please contact:

GC Tech.Europe GmbH

Harkortstr. 2
D-58339 Breckerfeld
Germany
Tel.: +49 2338 801980
Fax: +49 2338 801985
E-Mail: info@gctech.eu
www.gctech.eu

GC