

Injection moulding with composite to obtain a predictable aesthetic outcome

Clinical step-by-step with
G-ænial® Universal Injectable
and EXACLEAR transparent silicone

By Dr. Ali Salehi, France



Dr. Ali Salehi graduated in 2007 as a Master in Dentistry at the Faculty of Dental Medicine of Strasbourg University, France. During his Master course, he completed an Erasmus internship at the Faculty of Dentistry of the Johannes Gutenberg University in Mainz, Germany. From 2008 until 2015, he worked as a clinical consultant at the Department of Prosthetics of the University of Strasbourg. Since December 2015, he became a part-time Clinical-University Assistant in the same department. In parallel, he also works in his private practice in Strasbourg since 2011. His clinical work has been honored with several prizes, such as the 1st prize in the clinical category of the "European Talent Awards" of 3M ESPE (2015), the 3rd prize in the "Essentia European Facebook contest" of GC (2016) and the 1st prize at the Grand Prix of Aesthetic Dentistry of the French dental journal "Réalités Cliniques" (2017). Dr Salehi also actively participates in many trainings & conferences at various national and international events. His main topics of interest include dental photography, aesthetic dentistry, adhesive dentistry and minimally invasive dentistry.

Using the injection moulding technique, composite restorations are created by injecting the composite into a silicone key that is directly positioned into the patient's mouth. The main advantage of this technique is that restorations can be first modelled in wax on a stone model, and then copied and transferred in detail to the natural teeth. **For complex morphologies, challenging aesthetic cases or cases requiring reestablishment of the occlusal vertical dimension, a predictable result can be obtained and chair time reduced with this relatively simple procedure. Adjustments can also be made afterwards if needed.** Because these restorative treatments usually comprise extensive surfaces, the composite used should be strong and wear resistant enough and also offer the desired optical properties. G-ænial Universal Injectable is an ideal product for this indication thanks to its great thixotropy and excellent mechanical & aesthetic properties.

Injection moulding with composite to obtain a predictable aesthetic outcome

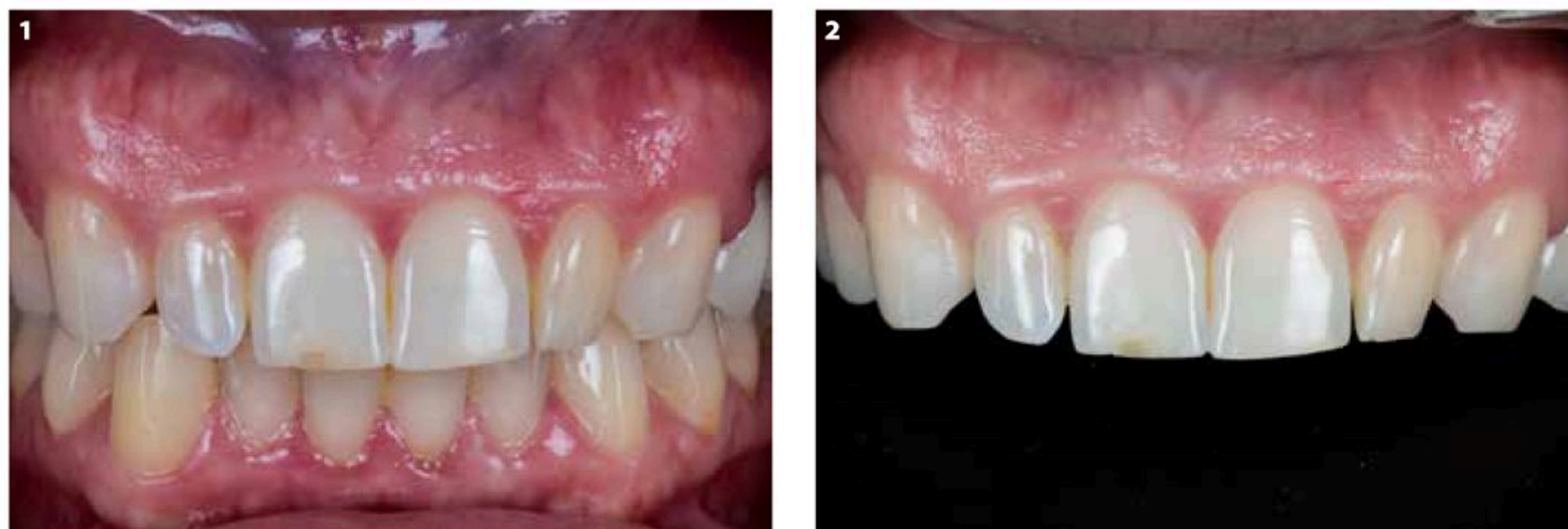

Fig. 1-2: Initial situation.

A 34-year-old, pregnant woman came to the dental office with the request to improve the aesthetic appearance of her smile. Her chief complaint concerned the shape of the lateral incisors (Fig. 1-2). She had already undergone a bleaching treatment and two veneer-lays on the heavily discoloured teeth 14 and 15, due to endodontic treatments covered with voluminous amalgam restorations in the past. After explaining the different options, she decided to go for a treatment with direct composites because of financial reasons and the idea of the minimally invasive nature of the procedure.

A wax-up was made of the desired tooth morphology that had been defined in consultation with the patient (Fig. 3). Next, a non-perforated metal impression tray was filled with a transparent vinyl polysiloxane material (EXACLEAR, GC) and placed over the stone model with the wax-up (Fig. 4-5). The tray's only purpose being to be used as a mould to create the key, a full-arch tray with a smooth inner surface was selected so that the silicone could

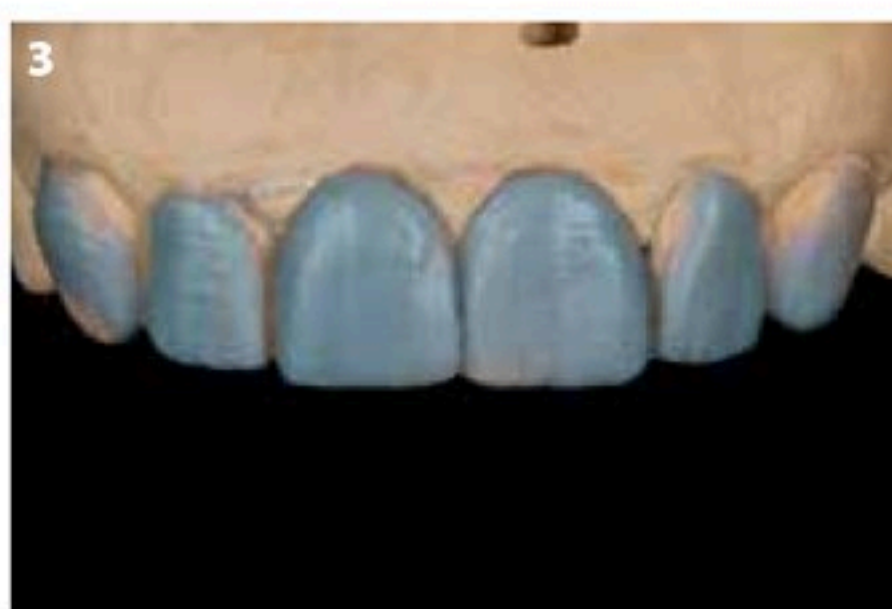

Fig. 3: A wax-up was made in consultation with the patient.

be retrieved easily in its whole and without damage (Fig. 6-7). Care was taken not to press too hard, so that all incisal edges were covered with a sufficiently thick layer in order to avoid potential tearing or deformation which could lead to a bad reproduction of the wax-up in the mouth of the patient. The tray was sufficiently filled to cover all teeth, up to the second premolars.

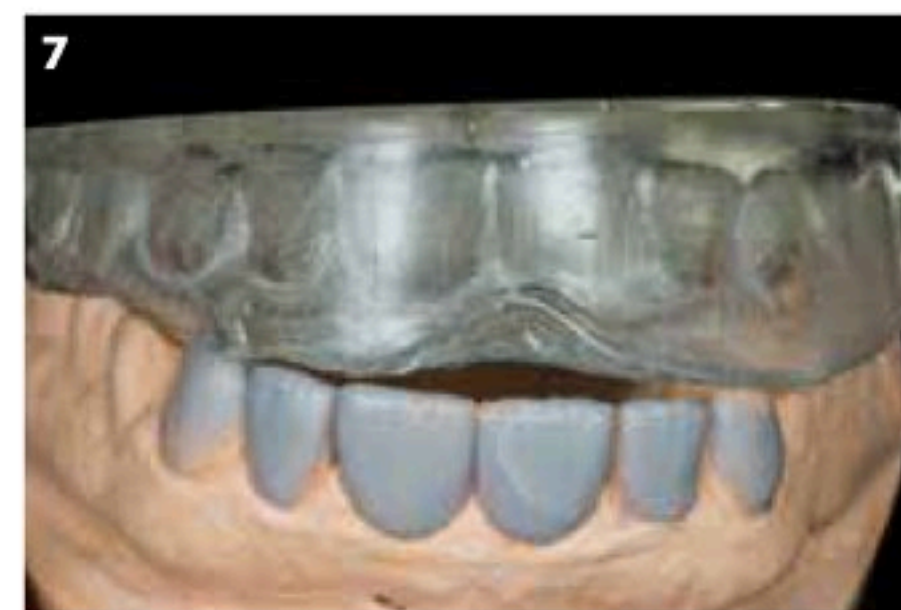
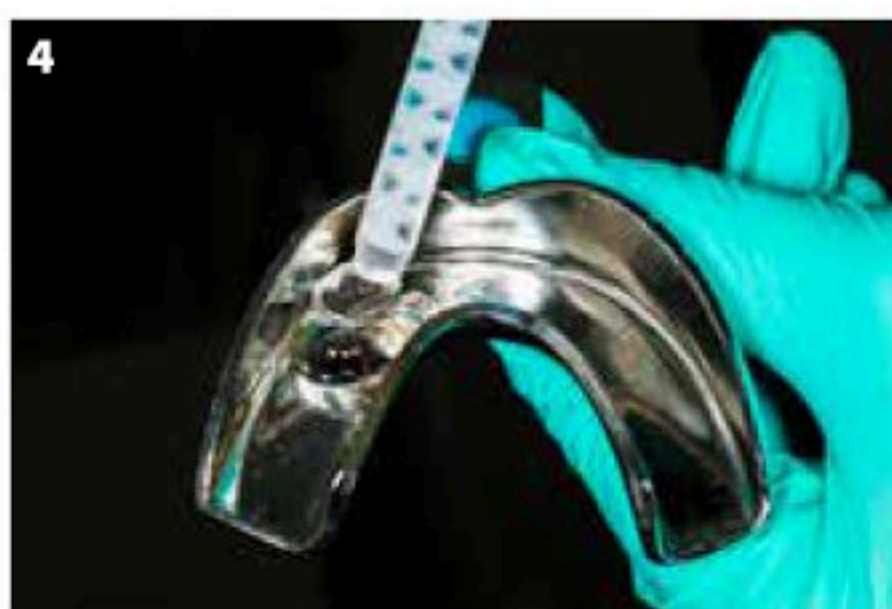
Fig. 4-7: A metal impression tray was filled with transparent vinyl polysiloxane (EXACLEAR, GC) and used to copy the stone model with the wax-up.

Injection moulding with composite to obtain a predictable aesthetic outcome



Fig. 8: A needle-shaped bur was used to drill holes through the silicone key ending in the middle of the incisal edge.

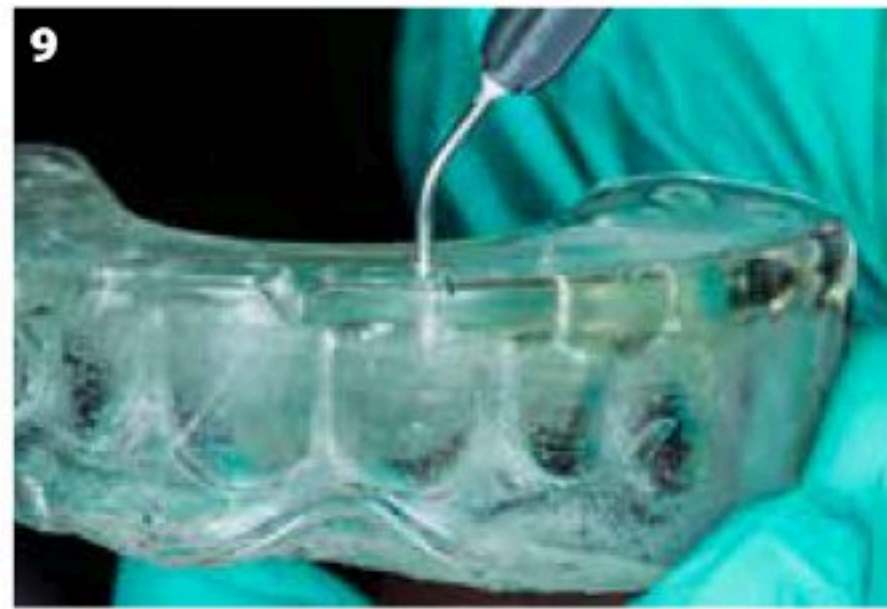


Fig. 9: It was checked whether the holes were large enough to enable the tip of the composite syringe to pass easily and completely.

As a rule of thumb, the silicone key should always extend so far that it includes at least two teeth distally from the teeth to be treated on both sides; this ensures stability of the key when it is positioned in the mouth and a proper reproduction of the aesthetic project for a more predictable

final result. In this regard, it should be noted that in a more ideal situation, a rubber dam could be used. In this case, the teeth should be sufficiently exposed through the dam and the clamps placed distally enough to avoid interference with the key. The latter should be trimmed cervically to

allow proper seating without any tension between the key and the rubber dam.

A fine, needle-shaped bur was used to drill the holes in the key through which the composite will be injected (Fig. 8). These holes were positioned at the middle of the incisal edge of each tooth, half-way between the distal & mesial borders, and made as small as possible but large enough to enable the tip of the composite syringe to pass easily and completely (Fig. 9). Care was taken not to damage the vestibular part inside the silicone key with the bur, to maintain the information of surface texture that had been created during the wax-up. This will guarantee a proper transfer and respect the idea of a predictable final aesthetic result.

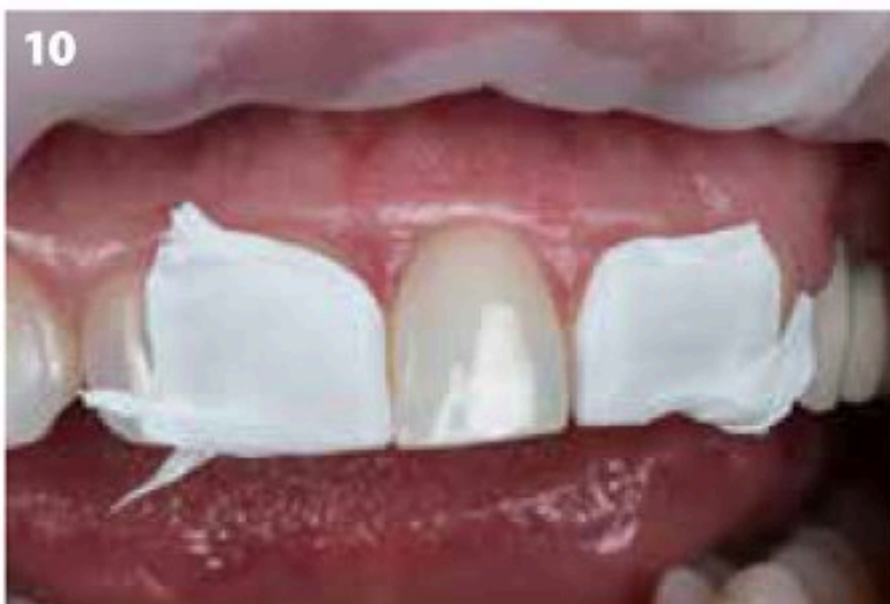

Fig. 10: Neighbouring teeth 11 and 22 were isolated using Teflon tape.

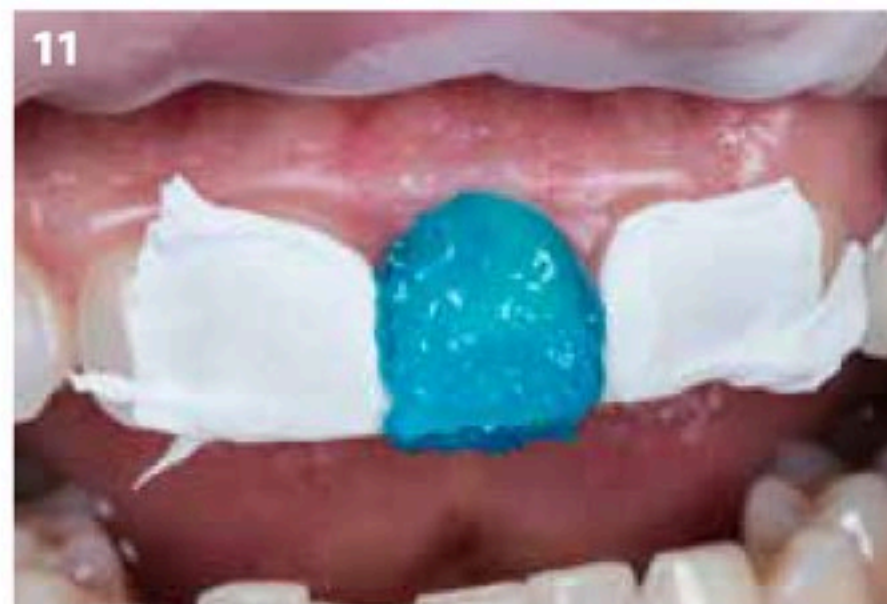

Fig. 11: The enamel of tooth 21 was etched to enhance micromechanical retention

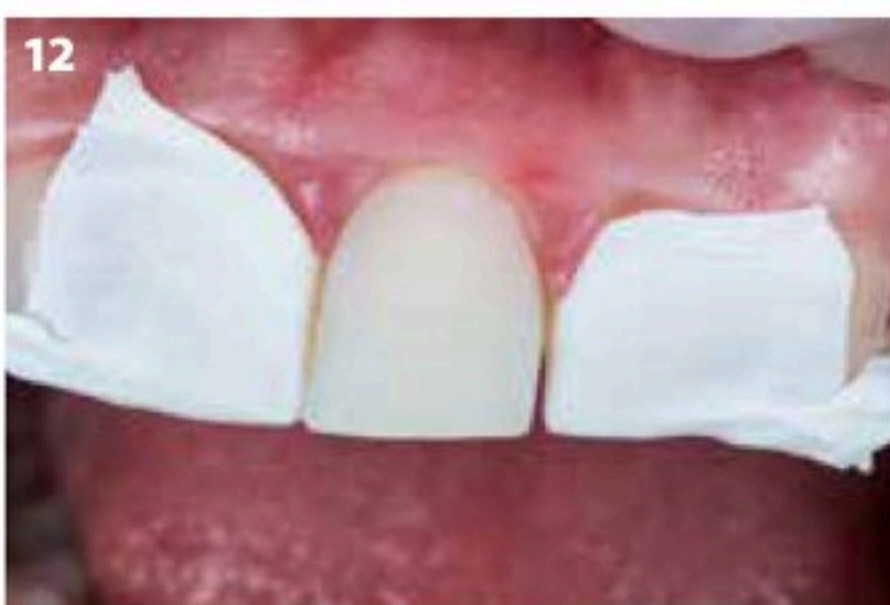

Fig. 12: After etching, the enamel surface showed a matt appearance.

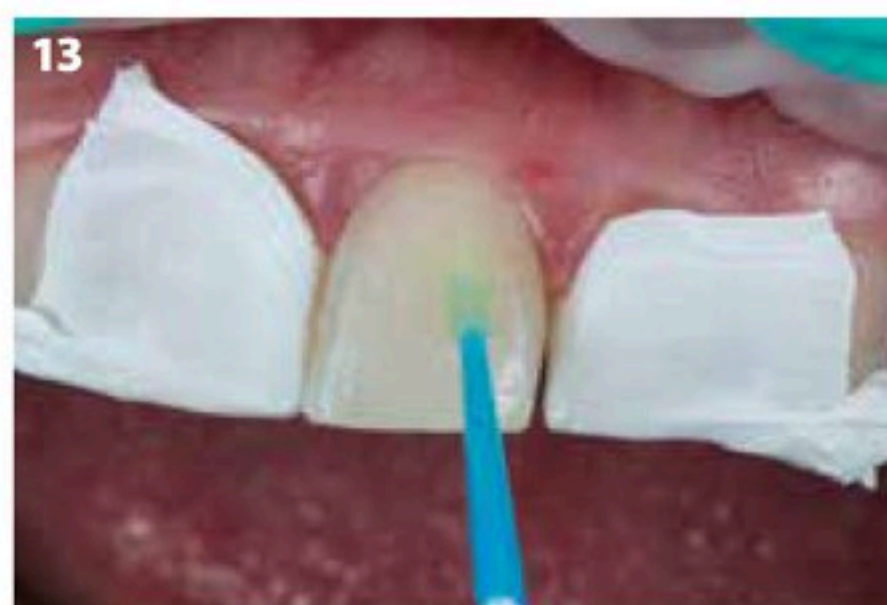

Fig. 13: The universal adhesive G-Premio BOND (GC) was applied in accordance with the manufacturer's instructions and light-cured.

After cleaning, the procedure was started with a central incisor. The neighbouring teeth were isolated with Teflon tape (Fig. 10). Then, the enamel was etched (Fig. 11) to create extra micromechanical retention, carefully rinsed and dried. A frosty appearance of the surface was obtained (Fig. 12). A universal adhesive (G-Premio BOND, GC) was applied, left undisturbed for 10 seconds and thoroughly dried with maximum air pressure for 5 seconds before light-curing (Fig. 13).

Injection moulding with composite to obtain a predictable aesthetic outcome

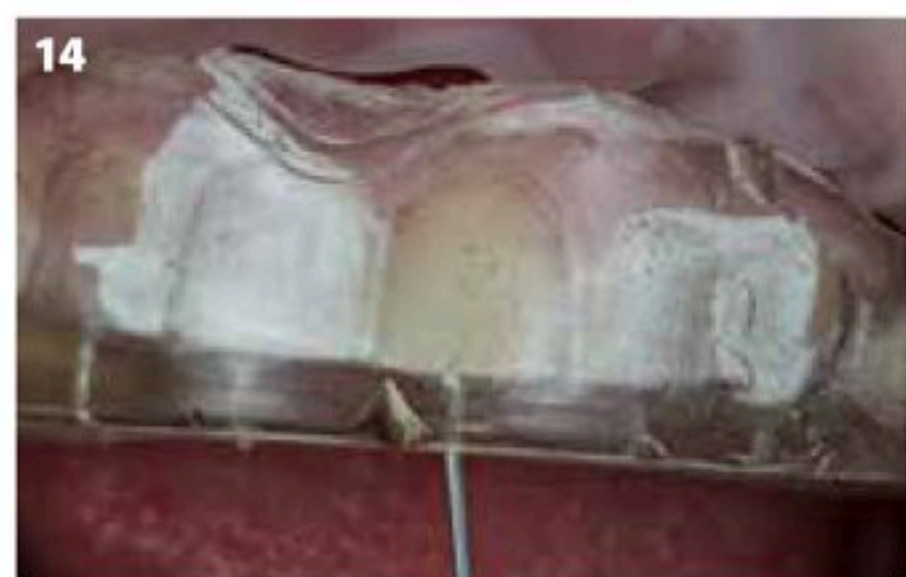

Fig. 14: G-aenial Universal Injectable (GC) was injected into the silicone key.

Next, the silicone key was positioned onto the teeth and the composite was injected (Fig. 14). G-aenial Universal Injectable (GC), shade A1 was selected for the procedure because of its high filler load and wear-resistance. The syringe was placed in the hole and slightly orientated towards vestibular. During the injection, a little bit of overflow is needed to ensure that all small voids at the margins and interproximal spaces are filled. This can easily be verified through the transparent key (Fig. 15). Next, G-aenial Universal Injectable was light-cured through the transparent silicone. After removal of the key, the excess was taken out with a surgical scalpel blade (blade #12, Swann-Morton; Fig. 16). Further finishing was done with a flame-shaped bur at the cervical margin, to correct any possible overcontouring, (Fig. 17) and with metal strips (New Metal Strips, GC) interproximally (Fig. 18). Metal strips are more rigid than transparent ones, which makes them more efficient and easier to use. Note that even though some bleeding might occur during this stage, finishing and polishing should be carried out thoroughly as smooth margins will help the gingiva to heal faster but also maintain the gingival health over time. The same procedure was repeated on the other incisors and the canines (Fig. 19-20).



Fig. 15: Due to the high transparency of the key, it can be visually checked if a sufficient amount of composite has been injected to cover the entire surface. The composite can also be easily light-cured through the key.

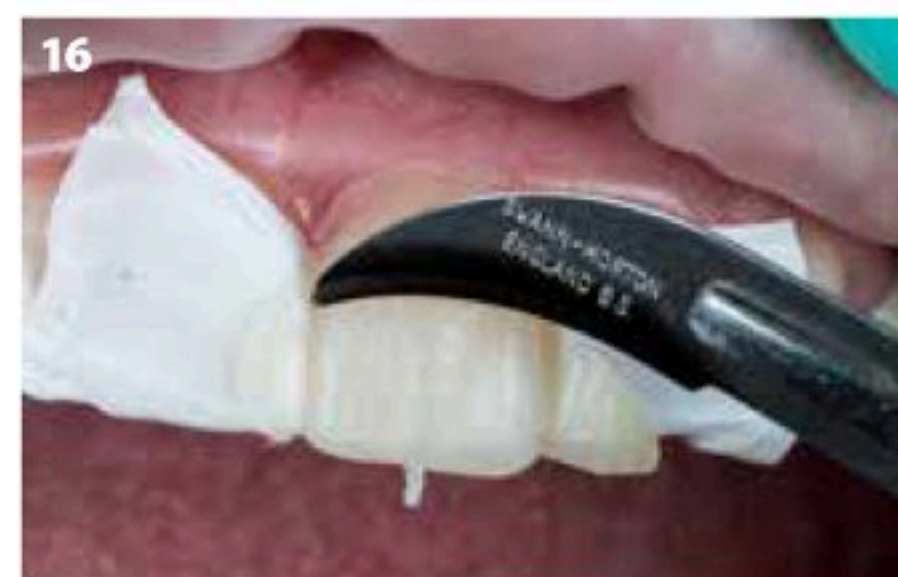

Fig. 16: The excess was removed with a scalpel (blade #12). Due to the presence of the Teflon tape, the excess did not stick to the neighbouring teeth and it was easy to remove.

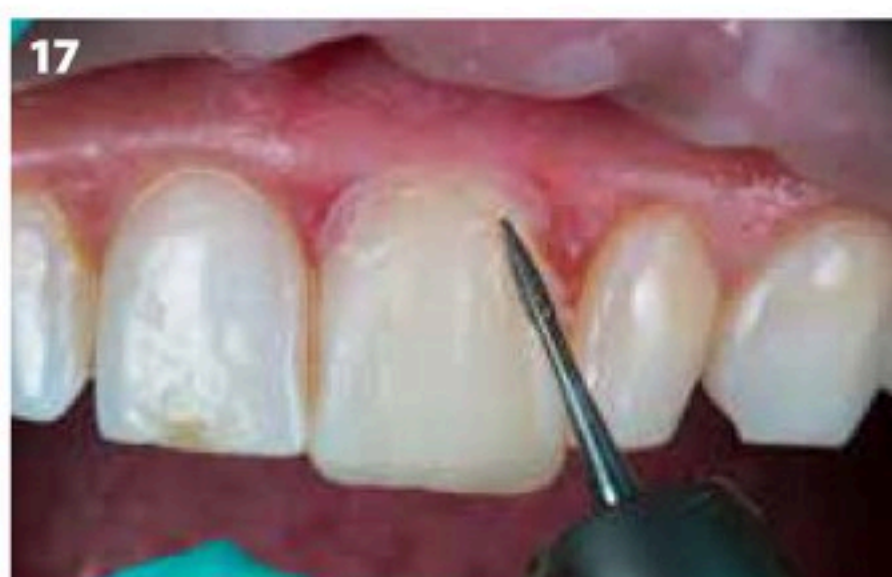

Fig. 17: A flame-shaped finishing bur was used.

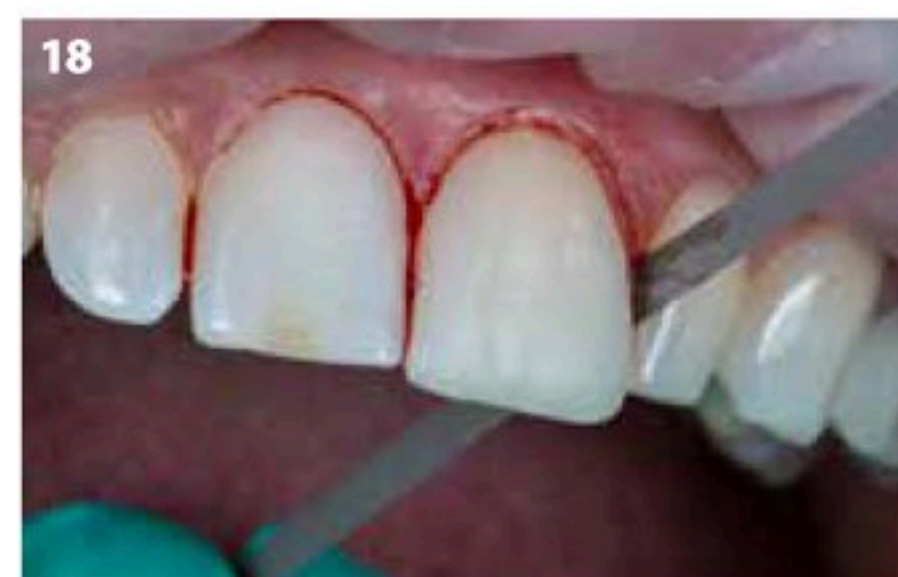

Fig. 18: Interproximally, the margins were finished with metal strips.

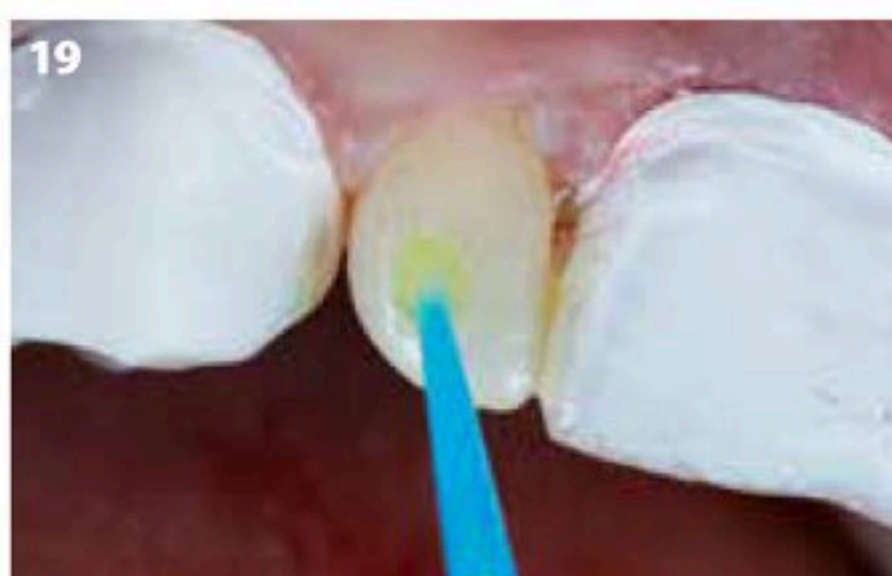

Fig. 19: The same procedure as shown for tooth 21 was repeated for the other teeth. Application of G-Premio BOND on tooth 12.



Fig. 20: Injection of G-aenial Universal Injectable (GC) into the EXACLEAR key.

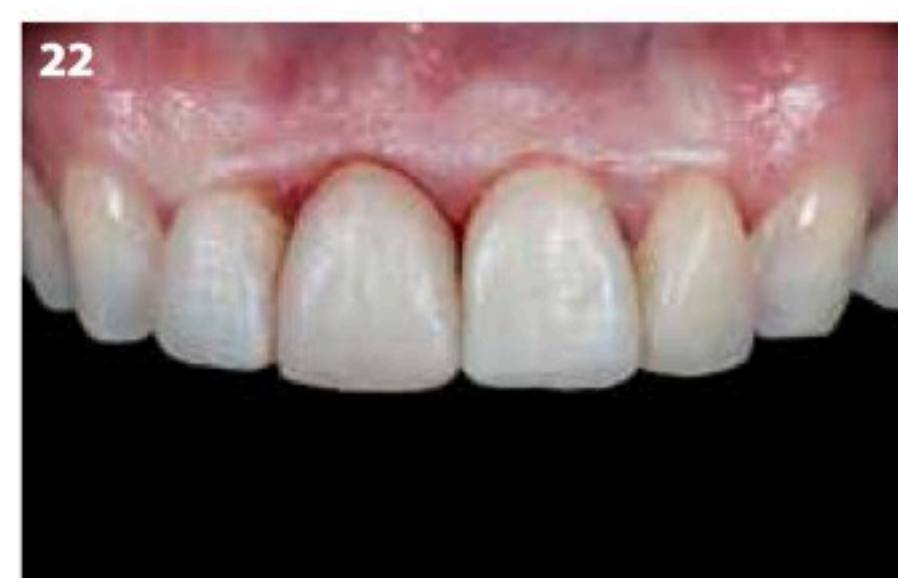
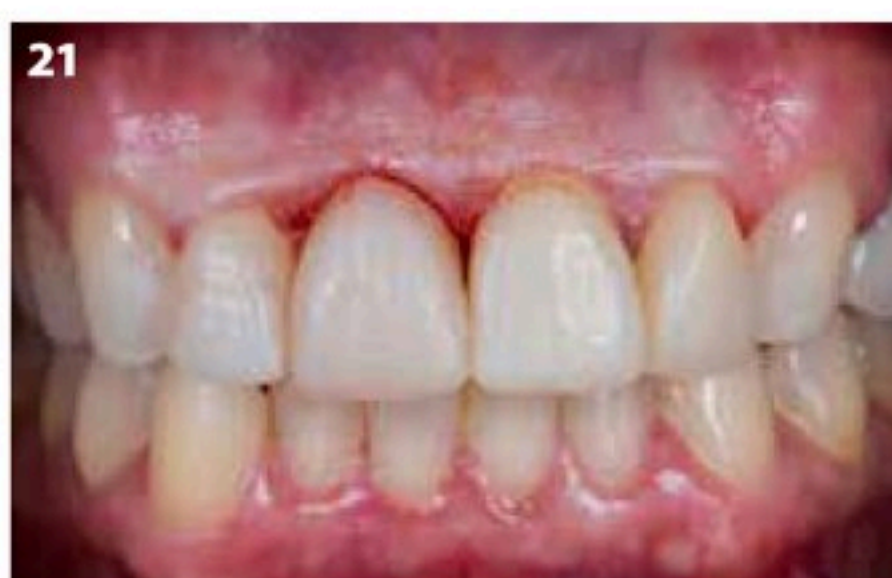
Fig. 21-22: Result immediately after curing the composite.

Injection moulding with composite
to obtain a predictable aesthetic outcome

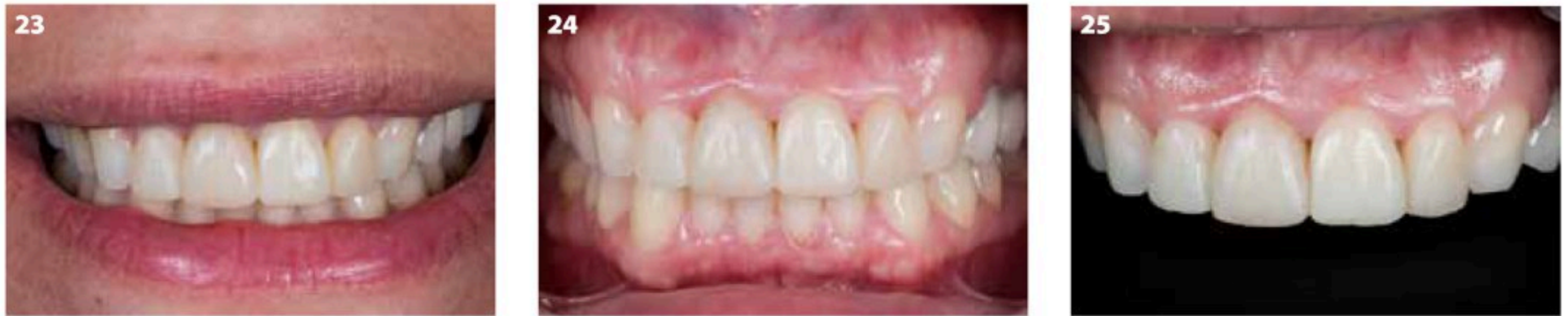

Fig. 23-25: Gingival healing 3 days after the treatment.

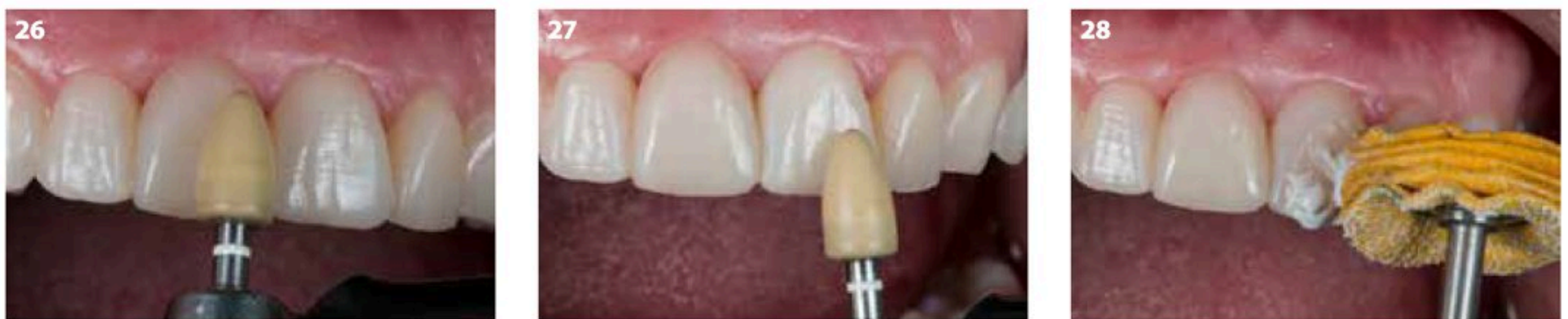

Fig. 26-28: Final polishing was done at the recall session.

Immediately after, it can be seen that the surface texture of the wax-up was transferred in detail to the direct veneers in the oral cavity, which gives the teeth a very natural and lifelike appearance (Fig. 21-22). Three days after the treatment, the gingival tissue had healed entirely (Fig. 23-25). In the recall session one week later, the surface was polished again with soft rubbers and cotton wheels with polishing paste

(DiaPolisher Paste, GC) (Fig. 26-28), to enhance the gloss while preserving the texture (Fig. 29-30).

The injection moulding technique is an easy approach that allows to plan restorations with complex morphology in advance and copy them in a predictable manner to the clinical situation. Even the surface texture can be copied from the wax-up,

which saves valuable chair-time. In order to have a long-lasting result, the composite needs to have good mechanical properties. **Considering the interesting properties of G-aenial Universal Injectable, being even stronger than many paste composites, it can be safely used for that purpose.**

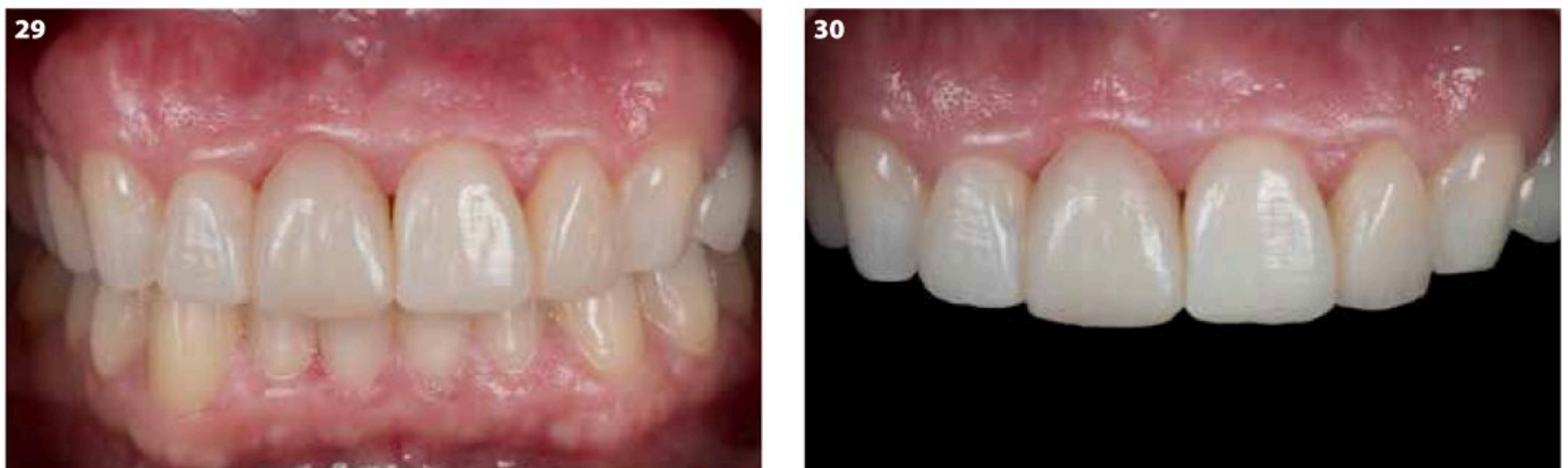

Fig. 29-30: Result after final polishing.